

CLINICAL Impressions®

PUBLISHED BY ORMCO CORPORATION • VOL. 4, NO. 3, 1995



**Dr. Takemoto
on Lingual
Extraction Tx**

Page 2

**Dr. Brady
on Copper Ni-Ti
Applications**

Page 8

**Dr. Mayes
on RPE Efficiencies**

Page 10

**Dr. Rosenberg
on Breakage
Costs**

Page 13


**Dr. Swartz
on Successful
Bonding**

Page 14

Dr. Takemoto

Lingual Orthodontic Extrac

by Kyoto Takemoto, D.D.S.
Tokyo, Japan



have been in orthodontic practice for almost 13 years and have two offices: the main one in Matsudo City, Chiba Prefecture, 15 miles east of central Tokyo; another in Roppongi, in the center of Tokyo. The number of lingual orthodontic patients and the demand for lingual orthodontics have shown a remarkable increase in Japan in the past 10 years, and I had just over 200 new lingual patients in 1994. My Roppongi office, named "E-LINE" (implying Esthetic Line), opened seven years ago, solely for lingually-treated adult patients.

It was in the early '80s that I first took on the challenge of lingual treatment in my main office. There was much trial and error in the early stages; cases that now would require only two years to treat lingually were taking more than three years to finish. Evolution of my lingual technique owes very much to my earlier patients for their full cooperation. In addition, it was fortunate that we had many excellent and knowledgeable teachers, such as Bob Smith, Craven Kurz and the late Jack Gorman, who encouraged me and demonstrated their invaluable lingual technique know-how. With the benefit of this excellent training and my 13 years of experience, my lingual treat-

ment is running smoothly and consistently, although it does require additional chair time. Now, in fact, I sometimes find it to be mechanically superior. I have overcome a couple of conventional technique limitations in extraction cases with my lingual mechanics which, in many cases, have treatment advantages over labial therapy.

It is my understanding that there are four different kinds of lingual appliances on the market today: Ormco, Fujita, Creekmore Enterprises and Forestadent. In Japan, Dr. Fujita developed lingual appliances in the mid '70s which were popular in Japan for a while. I used them until Ormco introduced their lingual appliances. They soon became mainstream in Japan after excellent treatment results obtained with them were published in the orthodontic journals and presented at numerous meetings. I have been using Ormco appliances since then and now use the Kurz 7th Generation Appliance with the horizontal main slot. Because of this slot design, tipping and anterior torque are controlled much more effectively and easily.

We encounter more extraction cases in Japan than are seen in the United States and Europe. As shown in Figure 1, 81 percent of total treatments are extraction.



Dr. Kyoto Takemoto has spoken and published extensively in Japan and abroad on orthopedics and lingual orthodontics. He belongs to the Japanese Orthodontic Society, the American Association of Orthodontists, the American Lingual Orthodontic Association and the Italian Society of Lingual Orthodontics. He is also an honorary member of the European Society of Lingual Orthodontics. Specialty certified by the Japanese Orthodontic Society, Dr. Takemoto completed his dental training at Tokyo Dental College in 1979 and his orthodontic training at Tokyo Medical-Dental University in 1981.

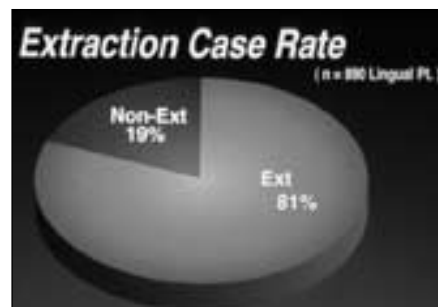


Figure 1. Comparison of extraction and nonextraction cases in Japan.

ion Therapy

There are two major reasons for this. One is that Japanese malocclusions are usually accompanied by severe arch-length discrepancies – you see many young girls and boys with high canines. The other is that there are so many bimaxillary cases with U1 and L1 tipping labially, making the profile very bad in conjunction with a small chin and flat nose (Mongolian features). It is obvious and well known that approximately 40 percent of adult patients who have such skeletal problems are much better treated with orthognathic surgery; however, many of them do not like to undergo operations. In my office, only 9 percent of lingual patients have been treated surgically. Many of them insist on solely orthodontic treatment even when they have very severe malocclusions.

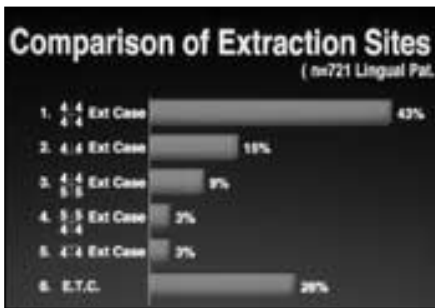


Figure 2. Comparison of extraction sites in Japanese cases.

A comparison of extraction sites is shown in Figure 2. Forty-three percent of all extraction cases are four-1st-bicuspid since there are so many cases of crowding. Twenty-five percent are unusual severe-extraction cases, where different teeth are extracted on right and left sides. Let's take a look at both the problems and advantages of extraction mechanics in lingual orthodontics.

There are four problem areas with lingually-treated extraction cases:

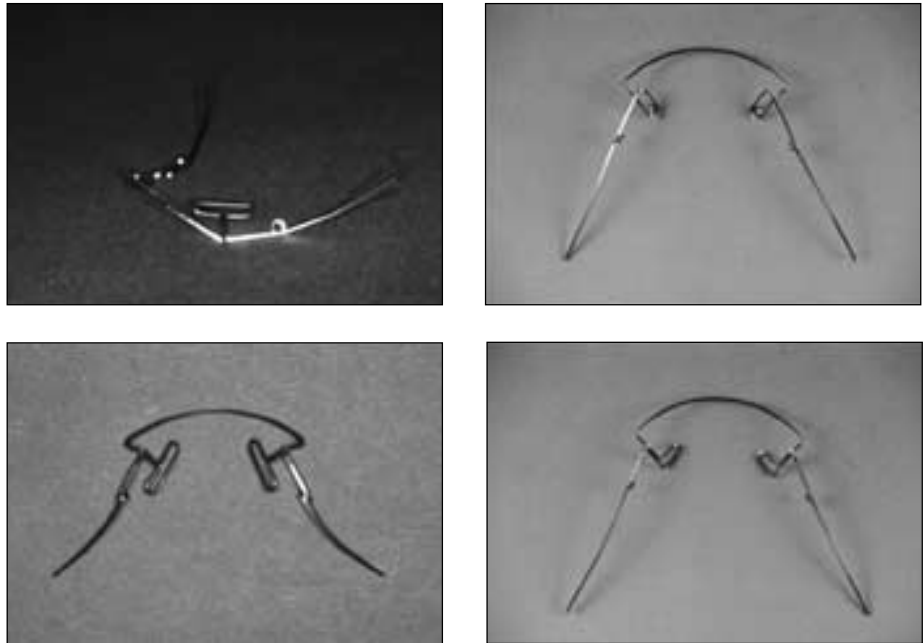


Figure 3. Arch form used for frictionless en masse retraction.

1. Bowing effect: The most serious problem and one requiring maximum care.
2. Alignment of crowded teeth: Longer time is required for leveling because of the short inter-bracket span.
3. Difficulty in coordinating the upper and lower arch forms.
4. Periodontal disease, especially in adult patients.

It is well known that there are two different bowing effects, vertical and transverse. Special attention is necessary so that neither takes place. This is a key to finishing extraction cases successfully.

It is most important in the leveling stage to prevent posterior segments from tipping forward. It is also essential to use up-and-down elastics before starting leveling when the position of the canine is too high to keep adjacent teeth from tipping. When retracting canines, it is preferable to

employ stiffer wires, such as .016 or .018 S.S., in order to prevent forward tipping of bicuspids and molars. During en masse retraction, it is critical to ensure that anterior lingual torque is sufficiently established and that the posterior teeth are not tipping forward. The arch forms most commonly used are shown in Figure 3; they incorporate closing loops on the upper arch. Compared with sliding mechanics, these arches accomplish bite and torque control more readily and they are, of course, free from wire friction. The L-loops are especially effective for intruding upper anteriors while maintaining torque during retraction. In closing the spaces on the lower, however, sliding mechanics are better and are used more often, as strong anchorage is provided by the molars and there is less chance for tongue irritation.

In applying the mechanics, "untipping"
continued on following page

Dr. Takemoto

continued from preceding page

bends should be incorporated into the archwire to prevent the vertical bowing effect. In addition, tie the archwire back mesial to the upper first molars in order to activate the loop. This method is considered best in minimizing the occurrence of side effects and to avoid applying force directly to the upper 2nd molars.

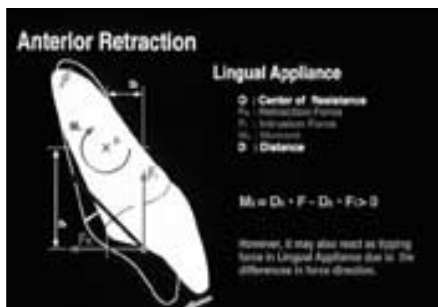
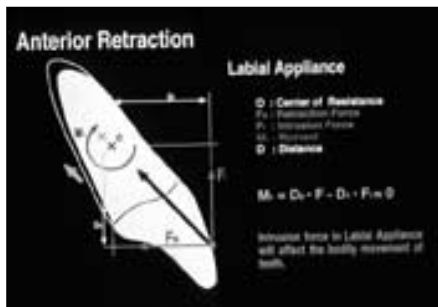


Figure 4. Momentum analysis of en masse retraction.

Shown in Figure 4 is a momentum analysis of en masse retraction. Fr is the AP direction force (or retraction force), and Fi is the intrusion force both in labial and lingual orthodontics. If it is assumed that the same amount of force is applied in both systems ($F_r = F_i$), the force direction is, as shown by the arrow, toward the center of resistance in the labial system. However, as shown below, the force direction is not directly at the center of resistance in the lingual system, and Fr and Fi will produce a lingual tipping force resulting in a vertical bowing effect.

As shown in the equation, momentum is almost nil in the labial system; however, it (M_2) is produced in the lingual system. That's the reason more intrusion and

torquing force is needed to retract anteriorly in lingual orthodontics than in a labial system if the same amount of AP direction (retraction) force is provided. We may need even more intrusion and torquing force with en masse retraction. With sliding mechanics, intrusion force is mainly provided by a compensative curve on stiffer wires and the bite plane effect. Retraction force (AP direction) is usually much greater. This is why the vertical bowing effect tends to occur.

Until a year ago, I used .016 x .022 S.S. arches with L-loops to provide more intrusion and torquing force for en masse retraction. I now use .017 x .025 TMA® with T-loops, as I found the latter is much better for en masse retraction in cases requiring more posterior anchorage. It also provides a more constant intrusion force. Incorporated into this T-looped TMA archwire are anterior lingual root torque, posterior lingual root torque, more gable bends, a compensative curve and a bigger bowing arch form. In any case, when anchorage is needed, high-pull headgear, transpalatal arches and Class II elastics should be used. I changed to TMA because the wire has a gentle force, the force applied in the AP direction is small (less than half that of SS) and seldom tips the molars forward, it minimizes anchorage loss and does not lose lateral function.

“Christmas tree” arches and bowing arches, as shown in Figure 5, are very effective for preventing the occurrence of the transverse bowing effect that can take place during en masse retraction. As shown in Figure 6, a distal rotation force on the upper molars is provided by the headgear. The same force is also provided during en masse retraction. The transpalatal bar should be adjusted at every appointment so that optimal mesial rotation force is applied.

It usually takes considerable time to correct crowding with lingual appliances, since the inter-bracket span of lingual brackets is shorter than that of labial ap-

pliances. I have been able to cut treatment time considerably by the adoption of C.L.A.S.S.* and the use of Ni-Ti® archwires, Ni-Ti coil springs and TMA archwires.

With lingual orthodontics, and especially when treating adults, special attention should be given to periodontal conditions, such as position of the buccal frenum, width of attached gingiva, gingival thickness and timing of extractions. Extractions are sometimes postponed depending on gingival conditions.

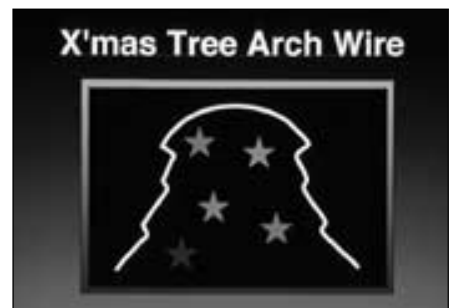


Figure 5. Christmas tree and bowing arches prevent the transverse bowing effect that can occur during en masse retraction.

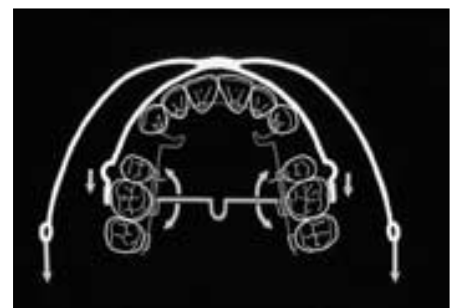

Figure 6. Distal rotation force on the upper molars is provided by the headgear.

*Custom Lingual/Labial Appliance Set-Up Service from Specialty Appliances

There are three major advantages of lingual orthodontic extraction mechanics:

1. Strong anchorage
2. Bite-opening effect
3. Functional-cusp control

A mechanical advantage of lingual treatment is that buccal root torque and distal rotation can be easily established with posterior teeth (so-called cortical bone anchorage). The posterior anchorage value of lingual orthodontics is higher than that of labial orthodontics, and the posterior anchorage value of the lower arch is higher than that of the upper arch. Lower 2nd bicuspids are, therefore, selected for extraction with lingual cases more often than with labial.

Posterior Anchorage in Lingual Treatment	>	Posterior Anchorage in Labial Treatment
Lower Anchorage	>	Upper Anchorage

Bite opening is mostly accomplished by depressing the upper and lower anteriors, while only a small amount of bite opening results from molar elongation. In many extraction cases, the amount of lower anterior depression is greater than the upper anterior. The mechanism for lower anterior depression results from the anteriors' edges contacting the bite plane of the upper anterior lingual brackets at an early stage. This bite plane effect of lingual brackets also causes posterior disclusion, especially in deep bite cases. In these cases, light-cured resin is recommended to build up the occlusal surfaces of lower 1st and 2nd molars to prevent them from elongating and to maintain occlusal function. In the process of treatment, the amount of resin will be reduced depending on the degree of depression of the anterior teeth.

It is generally thought that posterior teeth are extruded by the bite plane effect and

that, as a result, clockwise rotation occurs on the mandible. But I don't agree with this view. I believe that bite opening takes place mainly by depression of both upper and lower anteriors. There are many cases where depression is greater with the lower anteriors than with the uppers. In cases in which you want to actively depress the upper anteriors, T-looped TMA archwires are especially effective. The extrusion of posterior teeth is rarely seen, and there is less opening of the mandible.

Anterior DEPRESSION	>	Posterior ELONGATION
Lower Anterior DEPRESSION	>	Upper Anterior DEPRESSION

Lingual mechanics allow effective control of the functional (lingual) cusp because the appliances are positioned near it. Control of the upper lingual cusp is an effective way to reduce CO-CR discrepancy caused by initial contact of posterior teeth. In the lower arch, buccal appliances are placed on the buccal of posterior teeth as an auxiliary for control of the functional (buccal) cusp.

Discrepancies are caused primarily by initial contact between the functional cusps of the upper and lower 2nd molars. Lingual appliances are very effective in controlling lingual cusps of upper 2nd molars. As you see in Figure 7A, initial contacts are usually between upper and lower 2nd molars in centric relation. In 80 percent of them, the functional cusps are the lingual cusps of upper 2nd molars and the buccal of the lowers (Figure 7B). It can be said, therefore, that control of the functional cusps is important in orthodontic treatment in general. With lingual orthodontics, intrusion force is apt to be applied to upper lingual cusps, and thereby the mandibular clockwise rotation caused by extrusion of molars is kept to a minimum. On the lower arch, buccolingual control is accomplished by using crossover techniques. Figure 8 shows the direction of force resulting from molar

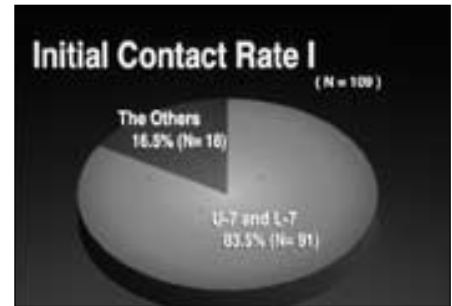

Figure 7A. Initial contacts are usually between upper and lower 2nd molars in centric relation.

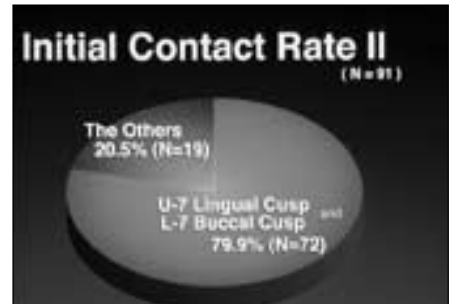

Figure 7B. Eighty percent of the functional cusps are the lingual of upper 2nd molars and the buccal of lowers.

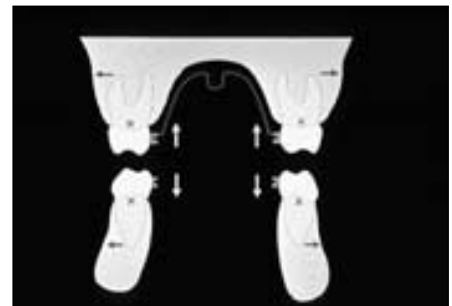

Figure 8. Direction of force resulting from molar contact.

contact. The upper lingual and the lower buccal are the functional molar cusps.

Until quite recently (and even now), many lingual orthodontists believed that open bites were contraindications for lingual treatment. I do not agree. Open bite cases are sometimes better treated lingually than labially. There are many advantages. For example, it is effective for tongue posture improvement (lingual appliances and lin-

continued on following page

Dr. Takemoto

continued from preceding page

gual elastics work as fences – the fence effect). I would like to show you two illustrative open bite cases:

The first case is a female patient, K. T., who just turned 27 when she first visited our office. The profile view shows a slight Class III tendency with chin protrusion. Severe open bite was observed. Because of lateral tongue thrust, lateral open bite was also severe and the upper right canine was very high. Arch-length discrepancies were -5 mm and -3 mm in upper and lower arches, respectively. She had a dolico-facial pattern and skeletal open bite. The treatment plan was to improve the open bite, extract four first bicuspid, and use a transpalatal arch for vertical control.

For initial leveling, Ni-Ti wires were used for both upper and lower arches. Up-and-down elastics were used from the initial stage for anterior segments in order to close the bite. After the six anteriors were leveled, .0175 square TMA was placed to establish torque. In-treatment photographs show en masse retraction of both arches. An .016 x .022 S.S. with L-loop was used for the upper arch, and sliding mechanics with an .016 x .022 S.S. wire were used for the lower arch. Power chain was set circularly from the lingual side of the 1st molar, around the mesial of the cuspid, then back to the buccal side of the 1st molar.

Space closure was almost complete in both arches by the 16th month and braces

were removed. Profile, frontal and lateral views look good. Cephalogram superimposition proves that the treatment was successful. There is no change in facial axis. Treatment has been accomplished with moderate anchorage in both arches. Angulations of the upper and lower centrals are good.

The treatment for this patient was done in a very short period of time – only 16 months. The patient was very cooperative and commuted regularly to my office in spite of the more than three-hour (one-way) train trip. She is now wearing a clear retainer. I was grateful for her excellent cooperation.

continued on page 18

Lingual Orthodontics – Why Do It?

The renowned lingual orthodontic pioneer Dr. Jack Gorman answered this query in his *Clinical Impressions* article completed just prior to his passing away two years ago: "First, it gives me a competitive edge in my community. Not only do I get the 'lingual or nothing' patients referred by other orthodontists, sometimes as far as 70 miles, but the perception of being a 'lingual expert' brings many adults into the practice who say they can't afford lingual but opt to start treatment with labial appliances. Frankly, I believe that our offer of lingual orthodontics is primarily responsible for about 50 patient starts a year – only one-half of this amount being lingual braces. Second, it allows me to treat some cases faster and better than I could using labial appliances...."

Dr. Takemoto's article reveals the secret to lingual orthodontic success – education

and experience! Lingual orthodontic training opportunities available around the world (listed alphabetically by instructor) include :

Dr. Robert Baker, Jr. and Dr. James Wildman will be the featured speakers at



Dr. Robert Baker, Jr.

Eastman Dental Center's Lingual Orthodontic Conference to be held November 3-5, 1995. Dr. Baker serves as Lingual Appliance Course Director at the Eastman Dental Center. The lingual orthodontic program has been in existence over 12 years, the oldest lingual orthodontic program in the world. Dr. Wildman is well known for his orthodontic product design. In keeping with its philosophy of allowing practicing dentists to participate in its evolving educational

programs, Eastman is sponsoring a continuing education course that will include the following topics:

Day One

- Proper selection of patients
- Beginning lingual biomechanics
- Bonding procedures
- Laboratory communication
- Case laboratory setup

Day Two

- Early treatment biomechanics
- Archwire selection
- Typodont course
- Selection, construction and placement of archwires
- Intermediate biomechanics

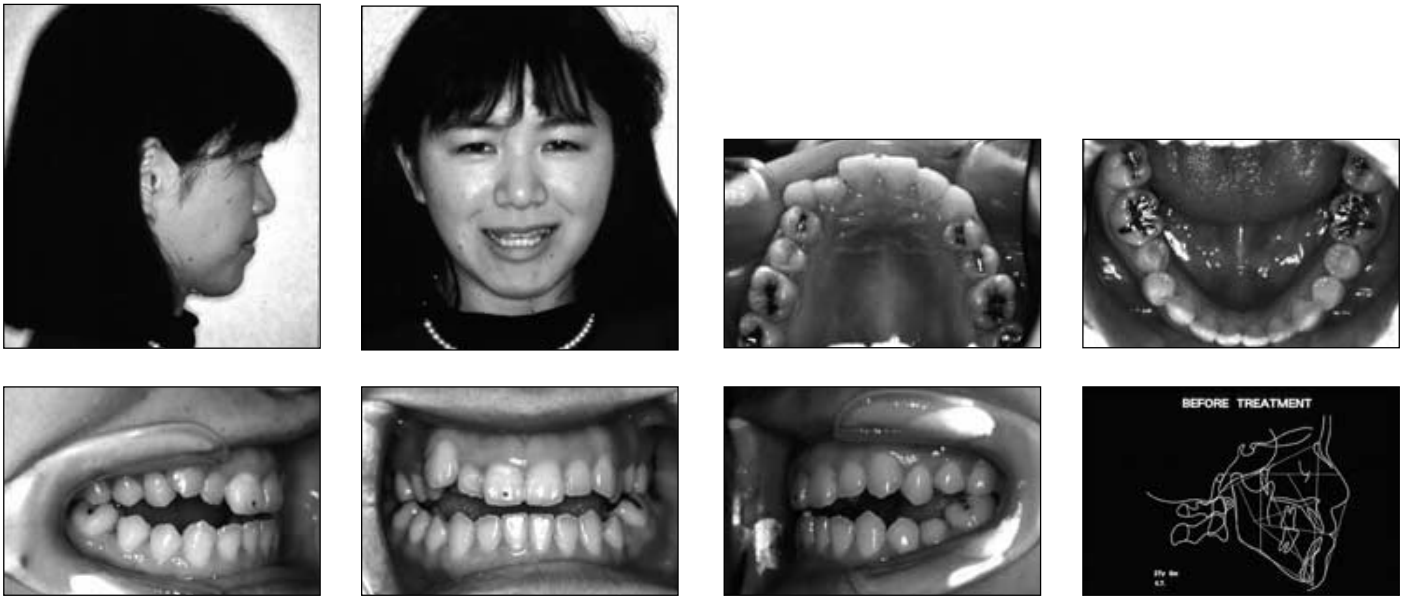Day Three

- Introduction to advanced case analysis and treatment biomechanics

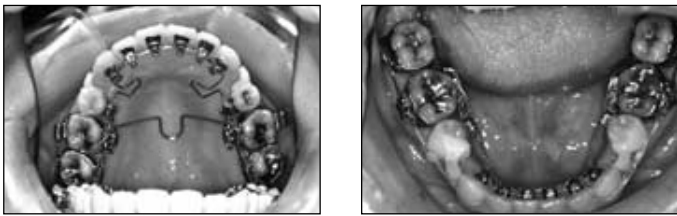
For further information, contact Sarah Williams, Eastman Dental Center, 625 Elmwood Avenue, Rochester, NY 14620, (716) 275-1143.

continued on page 20

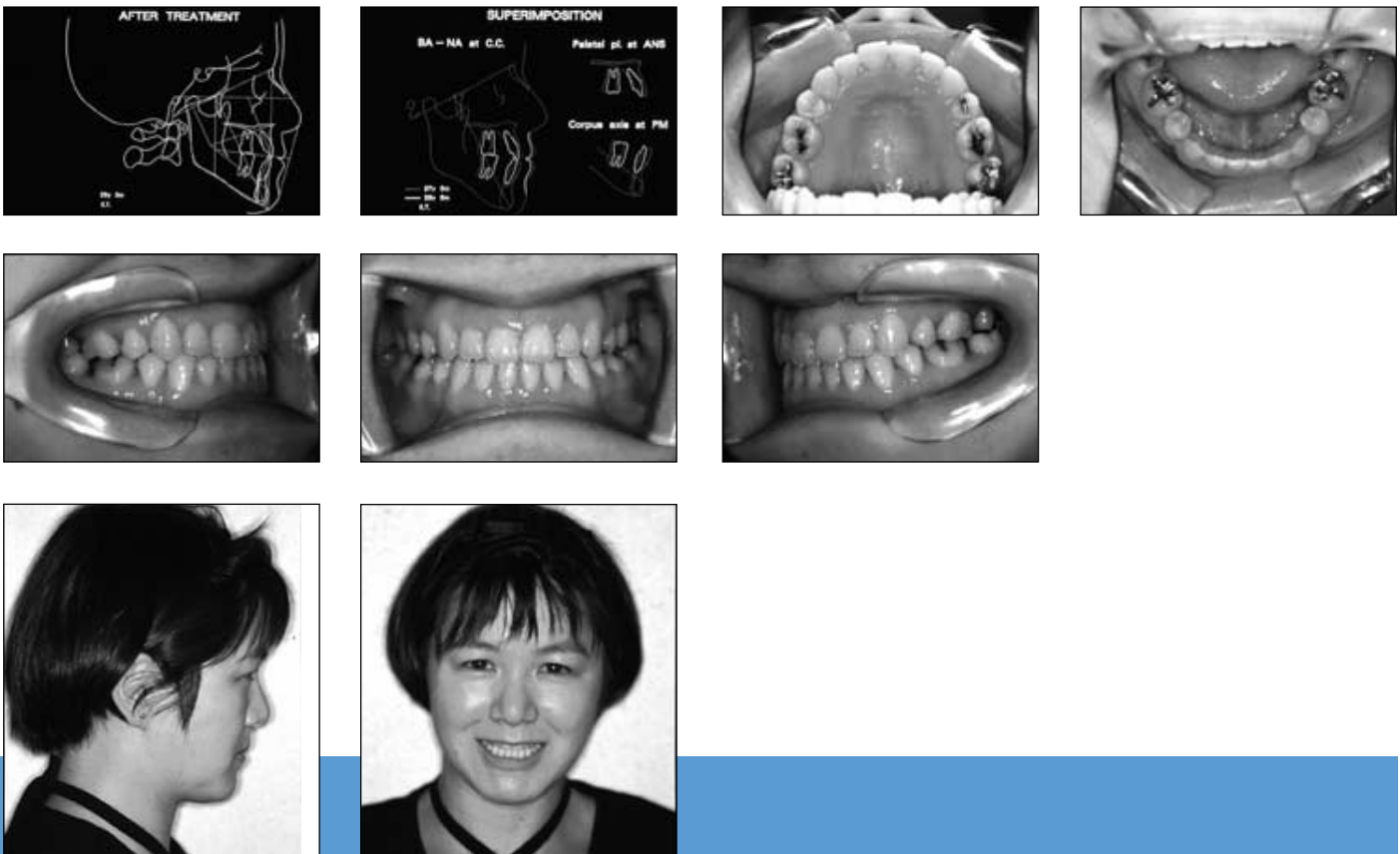
Case 1: Pretreatment – Patient K.T., D.O.B. 03/14/64, Age 27 years, 0 months.



En masse retraction of both arches.



Posttreatment – Patient K.T., 16 months treatment time.



Clinical Applications of Co

by Patrick B. Brady, D.D.S., M.S.
Dallas, Texas



The original idea for the orthodontic usage of nickel titanium (nitinol) wire was that of Dr. George F. Andreason. He was my mentor and head of the Orthodontic Department at the University of Iowa, College of Dentistry, during my residency.

I was in the Iowa orthodontic program between June 1969 and June 1971. The idea surfaced during a roundtable discussion of an article by Dr. William Buehler in the science section of a popular monthly publication. Dr. William Buehler was a U.S. Navy metallurgist who worked for NASA. He invented the nickel-titanium alloy which he termed nitinol. This alloy had unique properties: It was noncorrosive and had the ability to change crystalline

I strongly recommend the use of Copper Ni-Ti wire for patients with periodontal problems.

Dr. Patrick Brady has been engaged in the private practice of orthodontics in Dallas, Texas, for 24 years following his graduation from the orthodontic program at the University of Iowa. He serves on the clinical faculties of the Department of Orthodontics, Baylor College of Dentistry and of the Department of Oral Surgery, University of Texas Southwestern Medical School.

form with changes in temperature. Dr. Buehler termed the temperature at which this change took place the "temperature transition range," or TTR. Below the TTR, the alloy was a martensite; above the TTR, it was an austenite. The wire's shape was formed at a very high temperature, far above the TTR. It could then be cooled below the TTR and deformed to any configuration. As the wire was warmed through the TTR, it would then recover its original shape completely.

One of the first applications of nitinol was developed by NASA – antennae for space capsules. The wire was preformed at a high temperature, cooled and packaged. When the capsule was warmed by the sun in space, the package opened and released an antenna as the wire passed through its temperature transition range. Hence, Dr. Andreason thought of applying this wire to orthodontics below and above mouth temperature. Mouth temperature would be the temperature transition range. Dr. Andreason corresponded with Dr. Buehler about his idea. The first wires obtained from Dr. Buehler were "55" and "60" nitinol (55 and 60 represented the amount of nickel by percentage weight to titanium). The more nickel, the lower the TTR. The 60 nitinol had a TTR of 16°C to 27°C, while the 50 nitinol had a TTR of 32°C to 42°C.

Dr. Terry Bruce Hilleman, a fellow Iowa orthodontic resident, did a leveling force study utilizing nitinol wires that were cold worked in the martensite stage. These wires did not possess the ability to change crystalline form. They were found, however, to have four times the elasticity of stainless steel wire. This meant that the wire could be strained four times more than stainless steel wire without permanent deformation and then elicit small forces upon recovery. The original market-

opper Ni-Ti

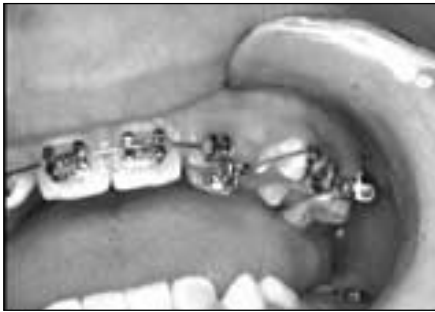

Figure 1. Engagement of palatally positioned canine with .016 35°C Copper Ni-Ti.

ing of the wire was done under this concept.

My master's thesis was a study entitled "The Determination of the Force Exerted by 55 and 60 Nitinol Alloy Wire During Its Recovery After Being Stretched." This study did utilize the TTR. The wire was stretched 8 percent of its length at a temperature below the TTR. As it was experimentally warmed, the forces exerted were within accepted ranges for space-closure mechanics.

There has been no usage of this type of space-closure mechanics to date. However, the TTR and superelastic properties are now being used in the leveling process. The 40°C, 35°C and 27°C Copper Ni-Ti™ archwires by Ormco are made for this stage of alignment. Dr. Rohit Sachdeva, a close friend and colleague of mine, developed Copper Ni-Ti wire with Dr. Suichi Miyazaki of Japan.

The reasons for adding copper to the alloy are:

- More accurate control of the TTR.
- More energy efficient; i.e., the force to tie in a rotation closely approximates the force required to rotate a tooth. The difference between the two is scientifically termed "hysteresis."
- It lowers the friction of the wire to make it slip easier along a bracket.

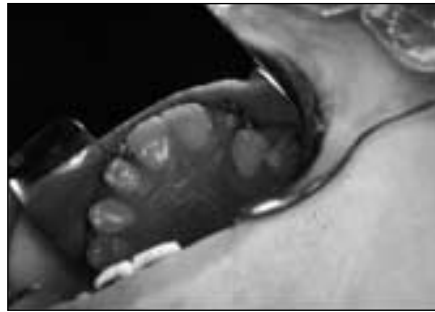

Figure 2. Easy engagement of high canine with .016 35°C Copper Ni-Ti.

In 1987, Dr. Sachdeva and I met at the Department of Orthodontics, Baylor College of Dentistry. I had just started as a part-time clinical faculty member and he was a full-time professor. Besides friendship, we had "nitinol" in common. Since our meeting, we have done several research projects utilizing nickel-titanium alloy, some already published and some in process. I consider Dr. Sachdeva the foremost authority on the applications of this alloy to orthodontics and look forward to new and innovative ideas from him in the future.

Because of my involvement with this alloy from the onset, I am extremely interested in its clinical application. Following are descriptions of some of the clinical applications of Copper Ni-Ti archwires in

our practice:


The main usage is in extreme leveling problems. Pictured in Figure 1 is a palatally positioned canine. Note the extreme deformation of the .016 35°C Copper Ni-Ti wire. Figure 2 illustrates the easy engagement of high canines. An important clinical observation needs to be pointed out about these two illustrations. Apparently, labiopalatal and labiolingual leveling of extremely malpositioned teeth is accomplished without severe reactions of intra-arch dental units. In the case of high cuspids, I would advise using inter-arch vertical elastics to avoid unfavorable buccal flaring of bicuspid and palatal tipping of incisor crowns. If this happens,

continued on page 21

Apparently, labiopalatal and labiolingual leveling of extremely malpositioned teeth is accomplished without severe reactions in intra-arch dental units.

The Single-Appointment M

by Joe H. Mayes, D.D.S., M.S.D.
Lubbock, Texas



Perhaps the most common problem facing orthodontists today, other than Class II's, is the constricted upper jaw. Ignored, it leads to dentofacial deformities and will relate directly to airway problems.

Remember, the same bone that forms the roof of the mouth also forms the base of the nose. For each 1mm of expansion at the midpalatal suture, the patient's airway is improved 28 percent.

If you have an in-house lab, a single-appointment expander can be fabricated and delivered in about 45 minutes. At the time records are taken, either double pour the upper impression or take a second upper impression for the lab. This allows the expander to be premade except for soldering and polishing. I prefer an all metal expander due to its cleanliness and lack of irritation to the soft tissue of the palate.

We also have discovered over the years that it is easier and quicker to cut, solder and polish than to make a lot of bends. Some bends will still be required but they are kept to a minimum.

The model is fitted with the expander screw in the lab, and adjustments and bends, as well as lengths of the legs, are corrected. A length of .060 wire is cut to fit from the mesiolingual of the upper

1st molar to the distal of the cuspid, the mesial of the 1st bicuspid, or the D. Any bends necessary to allow the .060 wire to lay against the tooth-palate juncture are made (.060 wire pieces may be soldered into place in order to effect contact with


the teeth instead of making bends [Figure 1]). The mesial end of the wire is rounded and smoothed at this time. This saves chair and lab time later.

When the patient presents at the fitting/delivery appointment, the upper 1st molars are fitted with bands (Figure 2) and an upper impression is made with the bands in place. Place the bands in the impression and hold in place with lengths of .016 stainless steel wire through the impression (Figure 3). Pour the impression with fast-set Kerr mounting plaster (Figure 4).

When the model sets (about 10 minutes), set the expansion screw (Figure 5) in place with the .060 wires (Figure 6) against the tooth-gingiva junction and solder (Figure 7). Lean the model to hold the .060 wire in place and solder one side at a time. Polish the appliance and it is ready to place and try in the mouth (Figure 8).

After the appliance has been tried and fitted (Figure 9), it is ready for cementation with glass ionomer cement. Decide at this time how much expansion is desired to determine the number of turns necessary. I like to expand at least a third more than I wish to end up with. Cement the appliance to place and then show the parents how to turn the expander. After they can

continued on following page



A native of Crane, Texas, Dr. Joe H. Mayes received his B.S. from Texas Tech University, followed by his D.D.S., M.S.D. and Certificate in Orthodontics from Baylor College of Dentistry. Dr. Mayes is engaged in the private practice of orthodontics in Lubbock, Texas, and has been actively involved in new product development.

Maxillary Expander

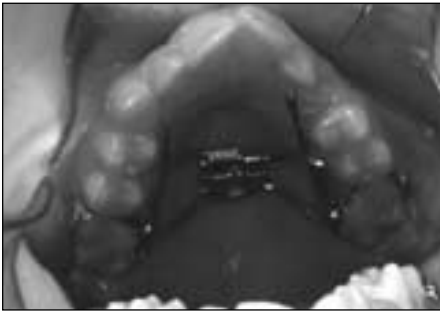

Figure 1. Upper expander – note the short piece of .060 stainless steel wire soldered to effect contact with the second bicuspid.

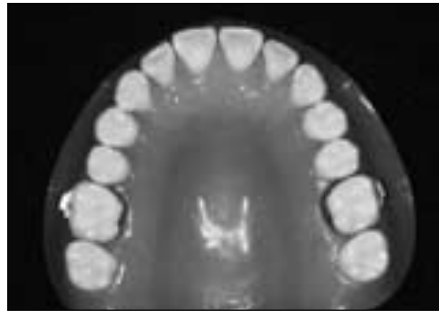


Figure 2. Bands fitted on the upper first molars.

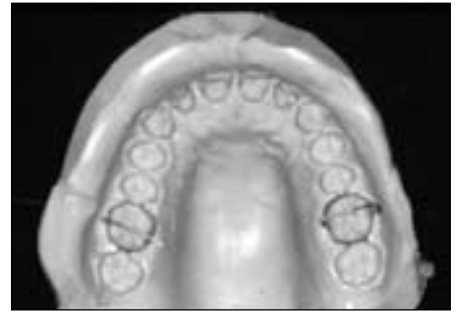

Figure 3. .016 stainless steel wire pieces prevent upper molar bands from floating into quick-set plaster.

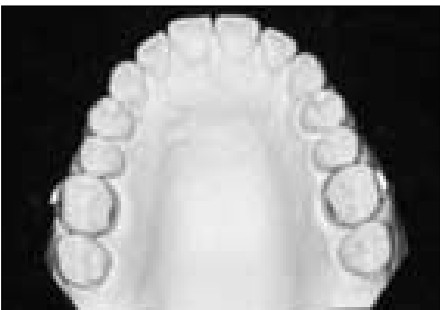

Figure 4. Model with bands in place. Remove .016 wires before separating model from impression.

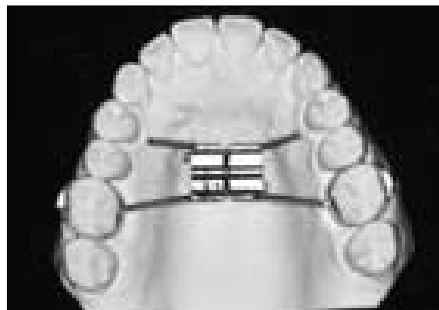


Figure 5. Premade and adjusted expansion screw on working model.

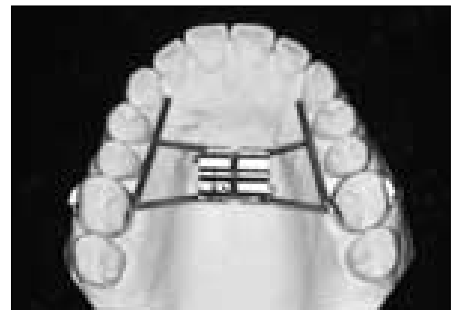


Figure 6. Expansion screw and premade .060 stainless steel wires ready to solder.

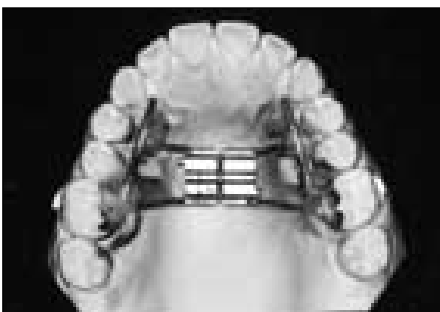


Figure 7. Appliance soldered.

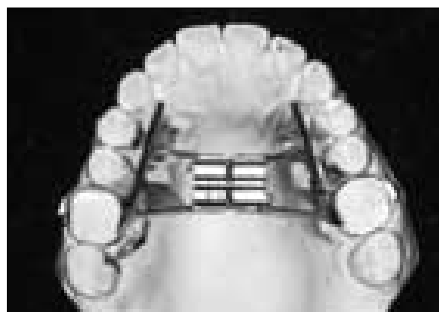


Figure 8. Polished appliance ready for checking in the mouth.

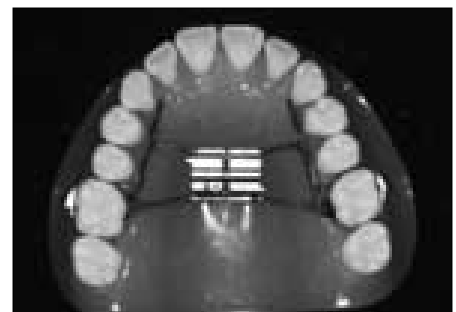


Figure 9. Single-appointment upper expander ready to be cemented.

Dr. Mayes

continued from preceding page

manage the turns properly, a score card to keep up with the number of turns (Figure 10) is given to them as well as a "throw-away" which gives the same instructions in writing (Figure 11). This throw-away is to remind them of the "do's" and "don'ts" and can be tossed in a few days when they are comfortable with the appliance.

My typical lower expander (Figure 12) is easily and quickly fabricated in the lab. With our streamlined procedures, it is not necessary to schedule several appointments for appliance delivery or to worry about lost separators and problems associated with their loss. Both patients and parents appreciate not having to return to the office so often. And our patients readily adapt to the hygienic all-metal framework. We find this particular expander ideally suited to our philosophy of correcting the width, then the A-P, and finally placing braces on Class I uncrowded cases.

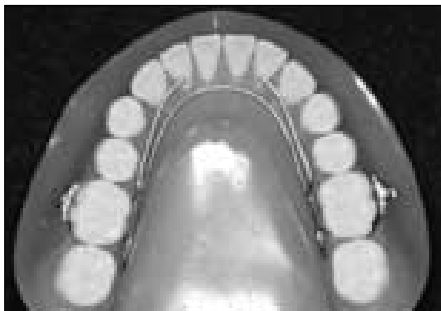


Figure 12. "Frozat" (fixed Crozat framework) – my typical lower expander.

PATIENT'S NAME _____		PRESCRIBED WEARING HOURS PER DAY _____		IF LOST, PLEASE RETURN TO: DR. JOE H. MAYES THE PUEBLO 4601-50TH STREET-SUITE 206	
NIGHT APPLIANCE RECORD CHART					
MONTH					HRS.
MONDAY					HRS.
TUESDAY					HRS.
WEDNESDAY					HRS.
THURSDAY					HRS.
FRIDAY					HRS.
SATURDAY					HRS.
SUNDAY					HRS.
WEEKLY TOTAL					HRS.

Figure 10. Score sheet for turns of appliance.

Figure 11. "Throw-Away" for expander.

**MAXILLARY EXPANSION APPLIANCES
(KORK)**

The appliance given to you will widen (expand) your upper jaw. The key that we gave you fits into the appliance. The key is put into the appliance and pushed backward to turn the expansion screw. Push the key backward as far as it will go, so that the key can be put into the appliance for the next turn. Either you or your parent can turn the expansion screw with the key.

The schedule for turning the appliance with the key is as follows:

_____ turn(s) daily for _____ days = Total of _____ turns.

Please follow the suggested schedule. Too many turns may cause discomfort. Too few turns will not produce the desired results.

If you feel discomfort, pain or dizziness, stop turning the appliance and call the office.

Please keep a long piece of string attached to the expansion key to avoid accidental swallowing of the key when turning the appliance.

A space will open between the upper front teeth as the appliance widens the arch. Do not get alarmed, this is an expected change. The space will disappear as the front teeth come back together after the desired expansion has occurred.

Please use your toothbrush to clean the teeth and appliance. With good oral hygiene, you will protect against cavities and gum disease.

If you have any questions about the appliance, please contact the office.

Joe H. Mayes, D.D.S., M.S.D.
4601 50th St., Ste. #206
Lubbock, Texas 79414
(806) 792-8116

The Real Cost of Breakage in Your Practice

by Jack Rosenberg, D.D.S.
Burke, Virginia

Over the years I, like you, have been made painfully aware of the necessity to practice in the most efficient manner possible. Rising costs and decreasing patient base have eroded our profitability. In the long run, maintaining our profitability will mean the difference between success and failure in orthodontics. Because of this, I have been looking at all the systems in my practice, trying to find ways to become more efficient and, therefore, more profitable.

Not long ago I was in the middle of my afternoon "rush" and I noticed (with an increase in blood pressure) that everyone in my office had something loose or broken. After a lot of hard work, "tap danc-

Ten percent of our production is spent repairing what was already accomplished.

ing," and increased tension, we managed to finish the day with a sigh of relief and a completely ruined schedule. At the end of the day my staff and I were so frustrated that we declared "war" on breakage.

Before we began our campaign to find the "perfect" bracket-cement-band-patient, etc., we wanted to know just how much breakage we really had and what type it

was, i.e., bands, brackets, wires. We also wanted to know how much time and money we were really spending repairing appliances.

We conducted a simple one-month study in which we recorded every problem associated with breakage. We tracked unscheduled appointments (emergencies) as well as problems found during scheduled visits. We assigned somewhat arbitrary times we felt it would take to make each repair. We could have been more specific; however, we decided to keep it simple. We also kept track of which assistant was with the patient to determine any training needs. Below is the result of our one-month study.

I. Emergency Visits

23 loose bonds	20 minutes each
5 loose bands	20 minutes each
10 "poking" wires	5 minutes each
7 broken K-hooks	10 minutes each

Total time = 680 minutes or 11.3 hours
11.3 hours divided by 3 assistants = 3.7 hours of appointment time

II. Scheduled Appointments

47 bonds	20 minutes each
17 bands	20 minutes each

Total time = 1,280 minutes or 21.3 hours
21.3 hours divided by 3 assistants = 7.1 hours

Total "re-do" time = 10.8 hours.

In our practice, this is almost a day-and-a-half per month of appointment time (scheduled or not) devoted to replacement and repair of broken appliances. Once you see it in these terms, the real cost is staggering. One-and-a-half days represents 10 percent of our total production. Ten percent of our production is

spent repairing what was already accomplished.

If that isn't bad enough, consider this. Despite our best efforts at scripting and communicating, most parents find returning to our office for repairs, regardless of who is at fault, inconvenient and frustrating—a patient relations disaster. Add to that the delay in treatment time that occurs when having to step back in archwire size and the frustration for staff and patients alike when running behind schedule. All in all, a bleak and costly picture.


Now the good news! Now that we know just how bad the problem really is, we are **STRONGLY MOTIVATED** to reduce the problem. Perhaps next year I can report all the things we did to reduce the cost of breakage in our practice.



Dr. Jack Rosenberg received his D.D.S. from Georgetown University in 1966 and his graduate training in orthodontics from Northwestern University, graduating in 1968. A Diplomate of the American Board of Orthodontics, Dr. Rosenberg has provided orthodontic services in northern Virginia for over 26 years.


Achieving a 95% Bonding S

by Michael L. Swartz, D.D.S.
Encino, California

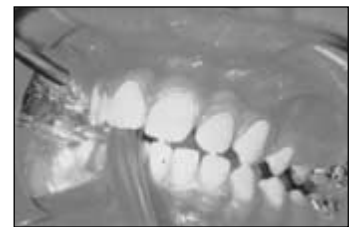
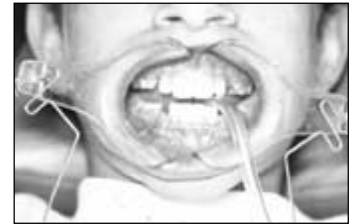

It is entirely feasible and practical to reduce your bracket bond failures to less than 5 percent when bonding through the second bicuspids. The time wasted replacing lost bonds is counterproductive and can cost the patient additional time in treatment. Rebonding can also create iatrogenic extrusive side effects. Most bond failures can be prevented with just a little extra effort initially. It can often take 20 minutes to replace a single bracket versus 45 minutes for an entire case. It therefore behooves you to spend the extra time necessary to reduce your failure rate. The following tips, techniques and suggestions should help you achieve at least a 95 percent success rate.

Proper Equipment: Many offices still have problems controlling water in their compressed air lines. A slight amount of moisture in the air can greatly reduce the ability of the resin to penetrate the etched enamel and thus reduce bond strengths. Be sure to check your air lines periodically and perform the required maintenance of your compressor and/or your in-line dryer. In my office, we use disposable clear tips on our three-way syringes. An added benefit of these clear tips is that you can readily detect any oil or water in your air line.



There are a number of cheek retractors available and a great difference of opinion on which is the best. The important aspect is to use a system of retraction and saliva control that provides good access and visibility. Many of the cheek retractors tend to laterally expand the cheeks at the expense of vertical closure. I think this is a function of the size of the device. The smaller ones, which are perhaps easier to place and more comfortable to the patient, tend to restrict your access. I have found that the best access is provided by the wire-frame type retractor (Masel catalog). These retractors have the buccal extensions to hold the Theta Dri-Angles® and the proper size to fit all with good access. Saliva control is achieved with a regular saliva ejector; the patient is told to bite down on it to improve access and to stabilize the mandible.



Wire-frame type cheek retractor in place.

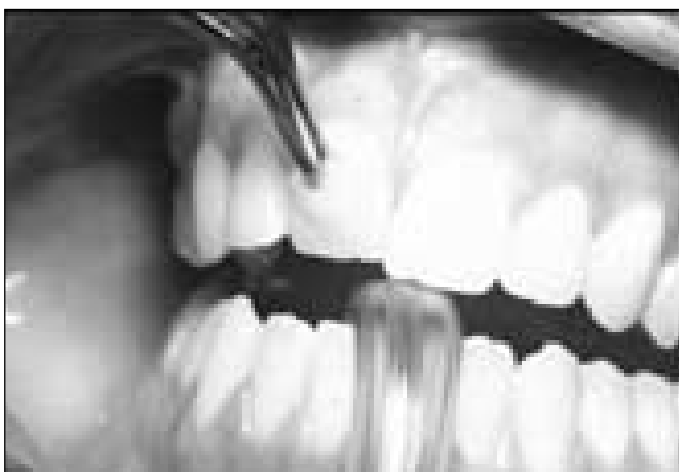The Pre-Bonding Prophylaxis: The intended purpose of the pumice prophylaxis prior to bonding is to remove the acquired pellicle (biofilm). The prophylaxis does this, but so does phosphoric acid. It is not necessary to prophylaxis the teeth prior to orthodontic bonding. (An exception might be a crowded-out tooth that the patient cannot effectively brush. In this case, you are removing plaque with the prophylaxis.) While eliminating the prophylaxis will not, in itself, reduce your bond failure rate, devoting the chair time spent on prophylaxis to more critical aspects will certainly pay dividends.

Enamel Etching: A great deal has been published on optimum etch times for orthodontic bonding applications. Several articles (in vitro studies) have suggested reducing etch times to 15 seconds. For many patients, 15 seconds would provide more than adequate etching. The problem is that individual variation in enamel solubility is great. Not only are we faced with great varia-

Dr. Mike Swartz earned his D.D.S. from the University of Southern California, School of Dentistry, in 1975 and his Certificate in Orthodontics from the University of California at San Francisco in 1985. He maintains a private orthodontic practice in Encino, California.

Access Rate

tion in the degree of etching between patients, but we also have large variations between teeth and within the same tooth. Since we do not know the enamel solubility of a particular patient, etching time is not critical. A range of 30 to 60 seconds is optimum for the majority of patients. For a portion of our patients



Light, continuous dabbing of liquid phosphoric acid.

(about 20 percent) whose enamel is more resistant to etching, reducing etch times much below 30 seconds can result in increased bond failures.

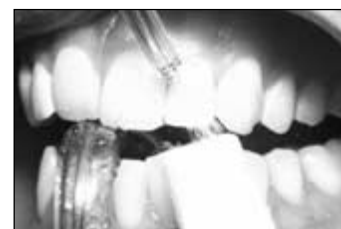The choice of liquid or gel phosphoric acid is debatable. While in-vitro testing has not demonstrated any differences between liquid and gel, I have been using liquid acid for my entire bonding career with a bonding failure rate below 5 percent. Since it is difficult to clinically distinguish the contribution of each step to the procedure, I have been reluctant to upset my success rate by switching to a gel. There is also some information that it is more difficult to thoroughly rinse and remove the silica and the by-products of enamel demineralization when using gels since they contain sub-micron silica particles.

My recommendation would therefore be to etch for 30-60 seconds using a liquid phosphoric acid (37 percent). I apply the liquid with a small cotton pellet held by a cotton plier (tweezer), lightly dabbing. I start dabbing on one side of the arch and work around the arch, dabbing with fresh liquid for 30-60 seconds. One arch is bonded at a time, starting with the upper arch.

Rinsing: Now we come to a step in bonding protocol that has been greatly overlooked and, in my experience, is critical in

achieving an optimum enamel bond. Rinsing the etched enamel has typically been a quick squirt of water. I have been in offices where a squeeze bottle is used to rinse. What must be recognized is that rinsing is not just to stop the etching process and to flush out the phosphoric acid. Perhaps more important, rinsing must also remove the byproducts of enamel demineralization. Phosphoric acid, in its demineralization of hydroxyapatite, leaves behind salts such as calcium monophosphate, which is gypsum-plaster! The sole purpose of etching enamel is to provide a micro-porous structure to which we can adhere. Leaving the porosity plugged with insoluble salts can greatly reduce the ability of the resin to penetrate; thus, bond strength is reduced.

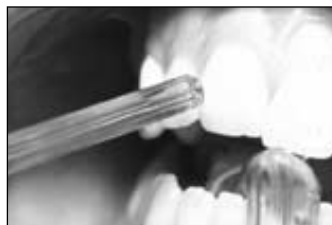Research on restorative procedures seems to indicate that a rinse of at least 20 seconds is optimum. While rinsing for 20 seconds for a single restoration is feasible, it would be impractical for an entire arch. As a compromise for the sake of time, five seconds per tooth is reasonable and accomplishes the tasks of neutralizing the acid and removing the byproducts of demineralization. Nevertheless, five seconds per tooth is significantly longer than most clinicians are currently doing.



A thorough rinse with a forceful air/water spray is required.

My technique is to hold the high-speed evacuator tip opposite to the direction of the air/water spray. I rinse while the assistant is preparing the adhesive and brackets. I believe that in this manner I can more accurately control the rinse. *Note: The three-way syringe can be adjusted to deliver a fine spray when pressing both air and water buttons. The button cap can be removed by lifting it off with a small screwdriver. The water valve underneath can then be adjusted by screwing it in or out. These valves should be replaced periodically if the water does not shut off completely when using*

the air alone. Rinsing is begun with the first tooth in the arch to which the etch was applied. Each tooth is rinsed for a full five seconds, collecting the rinse with the high-speed evacuator before proceeding to the next tooth. Since the



Use a clean, dry air source.

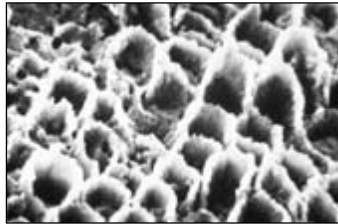
continued on following page

Dr. Swartz

continued from preceding page

etching time is not critical, there is no urgency to the rinsing step. The last tooth in the arch may receive a longer etch than the first tooth. This should not present a problem. As an option, you may quickly rinse the entire arch and then proceed to rinse tooth-by-tooth.

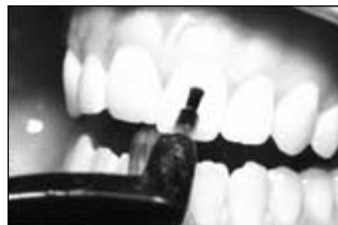Drying: Once all the teeth in the arch have been adequately rinsed, release the water button and begin drying while continuing to collect rinse and/or saliva with the high-speed evacuator. Continue drying with the air syringe, concentrating on directing the air stream into the gingival sulcus. Drying is complete when the teeth remain dull and frosty. No special drying agents or equipment, such as a warm-air blower, are necessary as long as the compressed air source is dry and without oil contamination. Before proceeding, examine each tooth to ensure that the bonding area has indeed been etched, as evidenced by the dull, frosty surface.



Scanning electron photomicrograph of properly etched and rinsed enamel.

The time between drying the etched enamel and application of the resin is critical. The exposed enamel rods are delicate and the surface is now highly reactive. Just as the bonding resin will be drawn into this reactive surface, so will saliva.

Sealant Application: The unfilled resins that are applied to the etched and dried enamel are all similar dimethacrylate resins which are hydrophobic (they do not like water). The etched enamel must be dry for the resin to be drawn in and establish the resin tags that provide the mechanical interlocking. However, once the resin has penetrated, it will prevent the absorption of moisture. This applies to all resins – light-cured, no-mix and two-component systems.



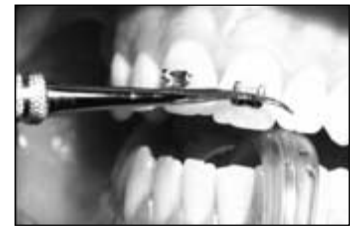Sealant application.

Therefore, once you have applied the unfilled resin (sealant), you can concentrate on bracket placement without being overly concerned with moisture contamination. Saliva, tongue control and cheek retraction are, of course, maintained during the entire procedure. The hydrophobic resin will preclude any saliva contamination of the underlying enamel. The bonding adhesive (paste component) will then copolymerize with the sealant layer, even if the surface of the sealant has some moisture present.

The procedure is to rapidly coat the etched and dried enamel sur-

face with a thin coat of the unfilled resin. Excess resin can promote bracket drifting and possibly reduce the cohesive strength of the final bond. Once all the teeth have been coated, you can proceed to place the brackets at a pace that is consistent with accurate bracket positioning. The unfilled resin sealant does not impose any time constraint.

Bracket Placement: Selection of the bonding adhesive should be based upon its handling properties: consistency, cleanup, and perhaps most important, the working time of the resin. The working time is the time between activating the resin(s) and its initial polymerization. This begins with mixing the two pastes together, placing a no-mix paste on the back of an activated bracket, or even exposing a light-cured paste to ambient light. When placing brackets directly, it is important to *press the bracket firmly onto the tooth surface*. By doing so, you express the excess adhesive, reducing or eliminating bracket drift and optimizing bond strength. It then is vital that the bracket be positioned well before the initial gelation of the bonding resin (self-curing systems) or well within its working time. If the bracket is moved once the adhesive has begun to gel, bond strength can be greatly reduced.



Place the bracket, press firmly, re-position, press firmly and leave the bracket undisturbed during the initial polymerization.

If you find that you lose brackets within the first few months of treatment and there appears to be adhesive remaining on the tooth, you can suspect that the bracket was moved during initial set. Another possible cause of this type of failure is placing a load on the maturing adhesive too early.

When using a self-curing adhesive, use a system with sufficient working time to allow you to place the brackets without feeling rushed. Take the time necessary to concentrate on placement accuracy. The no-mix materials, like System 1+®, are the fastest setting. If you require more working time, a two-paste system should be selected. Of course, light-cured adhesives provide essentially unlimited working time (they will begin to polymerize under normal room light in about five minutes or less).

Initial Archwire and Precautions: Another common cause of bond failure is placing a load on the brackets too early in the adhesive's setting time. All bonding adhesives require at least 24 hours to reach their maximum strength. This includes light-cured materials as well as the self-cure systems. With most self-curing materials, cohesive strength may only be about 50 percent of maximum by the time we normally place the first archwire.

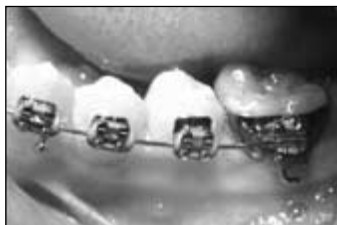The lesson to learn is to treat these still-maturing bonds with care. Do not attempt to gain full wire engagement at this appointment. Use large elastic ligatures and wait at least 15 minutes before placing the first (light) archwire. Also, be sure to caution your patients that during the first day they should be on a soft food or liquid diet. When rebonding a bracket (which will now only occur in less than 5 percent of your bondings), you must use only a very light wire until the following appointment.

Bonding Brackets in Deep Bites: Apparently, most orthodontists are reluctant to bond the lower incisors in deep bite cases until some bite opening has occurred. I have always bonded them from day one, with zero failures. With reasonable care in your bonding technique you will not lose the lower incisor brackets. The amount of force a patient can exert on the lower incisor brackets, when the vertical has been opened by occluding on these brackets, is significantly less than the forces applied to posterior brackets.

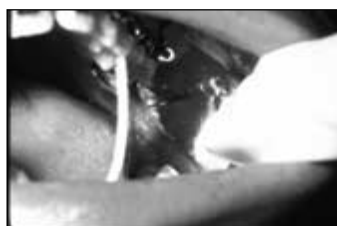Successful Bonding of Lower Bicuspid: The disproportionate failure rate on bicuspid cannot be totally attributed to posterior occlusal forces. The occlusion on lower second bicuspid brackets is certainly contributory to their failure. However, bonded first and second molar buccal tubes are not nearly as problematic as second bicuspid. A review of the literature indicates that a plausible explanation might be that the gingival portion of these teeth does etch or bond normally. The objective should then be to avoid bonding on the gingival third. A bracket placed at the extreme gingival edge of a bonding base that is carried farther occlusally (Ormco's gingivally-offset bracket) seems to accomplish this objective. Bond failures on lower second bicuspid have now been reduced from 20 to 30 percent to very acceptable failure rates of less than 5 percent.

Bonding Second Molars:

I have found a successful method of direct bonding second molars. Place one Dri-Angle on the buccal and another on the lingual. Use a saliva ejector and have the patient close down on the lingual Dri-Angle. Have the patient lean their head over to the opposite side. With a finger on the buccal Dri-Angle, retract the cheek. You should now have good visibility and access to the molar on one side. Bond the molar on this side and then repeat the operation on the other side.



The gingivally-offset lower second bicuspid bracket.



Bonding second molars.

Plastic Brackets – Spirits: Bonding polycarbonate brackets requires some extra care. The adhesion of acrylic bonding materials to polycarbonate is, at best, marginal when compared with mesh or ceramic brackets. The acrylic resins do not copolymerize with polycarbonate. The acrylic resins also do not form a chemical bond. The adhesion to polycarbonate comes about as a result of solvent dissolution of the polycarbonate surface. The applied acrylic becomes locked into the surface as the solvent evaporates and the polycarbonate solidifies. Therefore, this quasi-mechanical bond is technique sensitive.

A plastic bracket primer should be used to bond polycarbonate brackets. The plastic bracket primer contains the solvents necessary to dissolve the base of the bracket and also contains acrylic resins that become imbedded in the bracket base. The keys to successful plastic bracket bonding are using a primer that still contains sufficient solvents to do the job and the timing of priming and bracket placement. In order to dissolve the polycarbonate, the solvents must be volatile. They will therefore readily evaporate out of the bottle. Keep the bottle tightly capped when not in use and discard the primer if it becomes too thick. The bonding adhesive must be applied before the polycarbonate has begun to resolidify. Therefore, apply the bonding adhesive *immediately* after coating the base with primer. *Do not prime the brackets in advance.*

I have had good success with Spirit™ (and Spirit Plus) brackets using System1+ and the Spirit No-Mix Primer. I would strongly recommend *against using a light-cured material* when bonding plastic brackets. The bond of light-cured resins to primed polycarbonate is often very low. The light-cured materials do not contain the lower molecular weight resins that better wet the polycarbonate.

The foregoing discussion of plastic bracket bonding may well become outdated. Recent clinical evaluation of a plastic bracket with a mechanical bonding base (SpiritMB™) looks quite promising. A mechanical-retention base would not require the use of a primer and would likely do well with all types of bonding materials.

Porcelain Crowns, Plastic Crowns: Plastic temporary crowns can be either preformed polycarbonate crowns or made from poly-methylmethacrylate. Polycarbonate crowns can be treated just like the polycarbonate brackets. The bonding materials will copolymerize with acrylic crowns. Simply clean the surface of the crown, apply a primer or low viscosity sealant and bond the bracket. I use a multi-fluted finishing bur to clean and roughen the area of the bond. I have also achieved excellent success with System1+ to acrylic and to polycarbonate crowns.

continued on page 23

Dr. Takemoto

continued from page 6

The second case is a 26-year, 4-month-old female, Y.S., with a severe anterior open bite and crowding. I was quite astonished when I first looked into her mouth. Crowns of the upper incisors and canines were all laminate veneered but very poorly done. I was surprised by the technical level of the general practitioner who treated her; I had never encountered such poor treatment. The patient had a very narrow upper arch and posterior crossbite. This was a high angle case and protrusion of U1 and L1 was observed – typical skeletal open bite.

After lateral-segment corticotomy, we used a palatal expander before starting treatment in order to expand the narrow upper arch. An in-treatment photograph shows the occlusal view after the upper arch was amply expanded. We then placed bonds and bands and extracted four bicuspids.

An .016 Ni-Ti was placed as the initial archwire for both arches, and up-and-down elastics were used to close the bite. After leveling, the upper left canine was partially retracted with .016 S.S., and incisors and canines were then leveled. Torque control was established with .0175 square TMA after leveling was complete. At this stage, en masse retraction was done for both arches, the upper arch with

Open bite cases are sometimes better treated lingually than labially.

loop mechanics (closed helical) and the lower with sliding mechanics.

In this type of case with little need for upper anterior root torque (U1 was flaring out before treatment), I always use closed helical loops for the upper arch. When using sliding mechanics for the lower arch, I also use power chain circularly (both lingual and labial) between canines and 1st molars. A transpalatal arch and headgear were used for anchorage, as well as Class II elastics for three months – a maximum anchorage case. U1 and L1 are well retracted and tooth angulations are good. Active treatment time was 28 months. The profile is marvelously improved and the case is beautifully finished.

Even with the problems and additional considerations discussed, lingual treatment is clinically recognized as very effective and offers a number of advantages. Those cases that used to be contraindicat-

ed, such as Case 2, are now treated by lingual appliances without any problems. There is no substantial difference in treatment time or results between lingual and labial orthodontics.

Lingual mechanics have been greatly improved in the past several years. I have, from time to time, encountered many new problems that I solved through trial and error. Sometimes the problems do require extra attention, and chair time is apt to be long, especially in the earlier stages of the learning curve. Lingual orthodontics, I am sure, is the ultimate goal for orthodontics, as most patients want to be treated by invisible braces. Lingual treatment processes, therefore, should be as simple as labial, and we need to become accustomed to them. It is necessary to train ourselves diligently and try to provide our patients with invisible orthodontics, giving them the ultimate in comfort and happiness.

European Society of Lingual Orthodontics

The second symposium of the European Society of Lingual Orthodontics (ESLO) will be held in Monaco on March 21-23, 1996. Twenty years after the creation of lingual orthodontics, 40 lecturers will speak on:

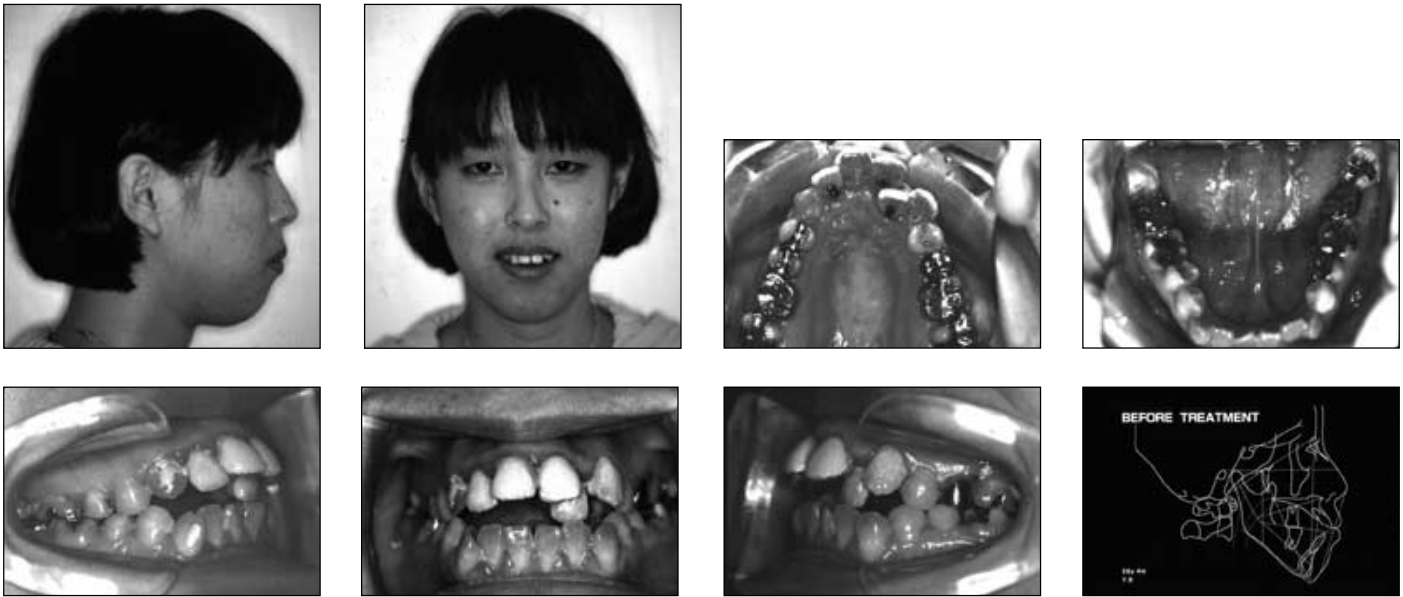- Laboratory and Computer Science: European and American Approaches
- Non-Extraction Therapies
- Optimizing Lingual Appliance Mechanics

•Case Studies

ELSO President and Chairman:
Dr. G. Altounian
Scientific Presidents:
Dr. D. Fillion, Dr. J. F. LeClerc

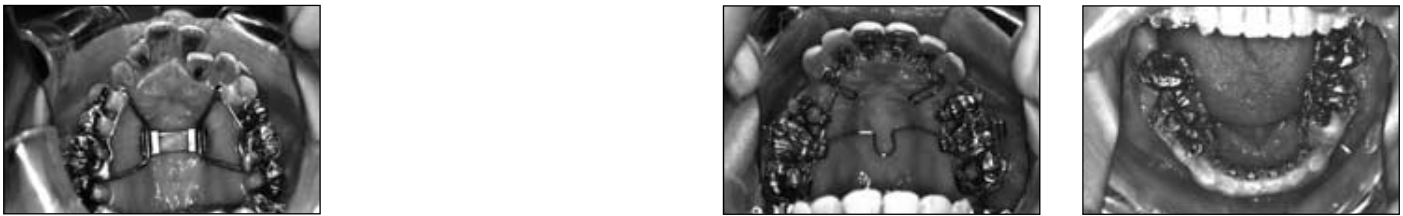
For further information, contact:
Dr. G. Altounian, 2 Rue de Malleville
Enghien Les Bains 95880, France
Fax (33-1) 39 64 95 54

Case 2: Pretreatment – Patient Y.S., D.O.B. 11/16/65, age 26 years, 4 months.

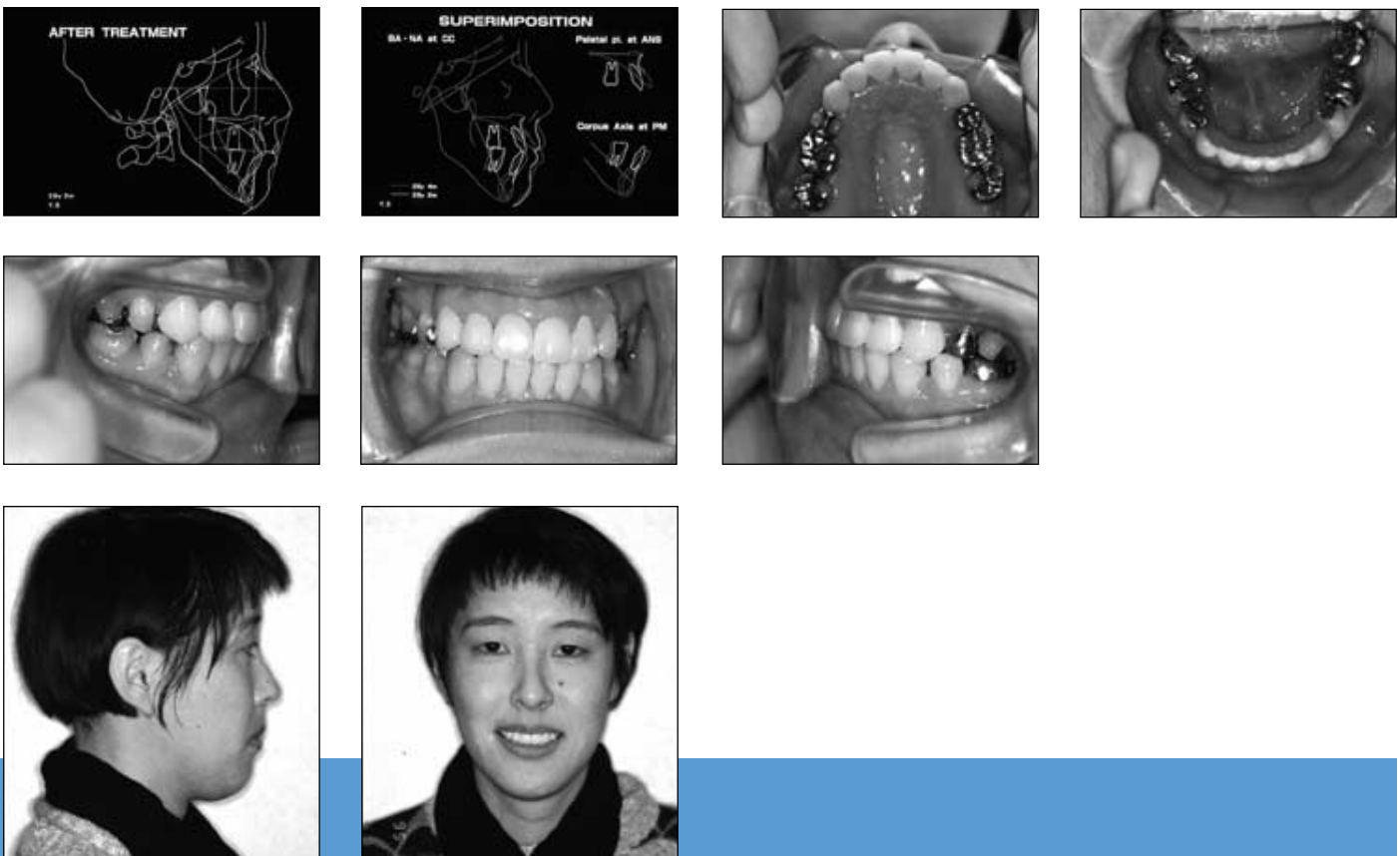


Below Left: Occlusal view after expansion following lateral-segment corticotomy.

Below Right: En mass retraction of both arches – frictionless mechanics for upper and sliding mechanics for lower.



Posttreatment – Patient Y.S., 28 months treatment time.



Lingual Orthodontics

continued from page 6

Dr. Didier Fillion has practiced lingual orthodontics exclusively in Paris since 1987. He has held courses in lingual orthodontics around the world. He periodically conducts hands-on, in-office courses in French or English, with his next course scheduled Nov. 19-21, 1995. Course goals are to demonstrate in detail all the lingual treatment steps: laboratory procedures, bonding, archwire sequences, sliding and segmented mechanics and permanent retention. Attendance is limited to five participants who, upon course completion, should be able to treat any type of case.

The courses include eight hours of lectures, three hours of learning laboratory procedures with a lingual technician, six hours of typodont exercises and five hours of clinic time. Laboratory procedures are primary – achieving an accurate bracket position is critical to resolving problems during treatment. In the clinic, enamel reduction and surgical, extraction and non-extraction treatments are demonstrated, and participants are able to discuss the cases.

For information or registration, contact the office of Dr. Fillion at:
4, Avenue Georges Mandel
75116 Paris, France
Tel. 47 04 27 93, Fax 47 55 18 33

Dr. Courtney Gorman conducts an annual typodont workshop on lingual orthodontics for the Continuing Education Department of the Indiana University School of Dentistry. He also serves the school as Associate Professor in the Department of Orthodontics, his responsibilities including lingual orthodontic training.

The next course will be held on February 9-10, 1996. The course includes an introductory session followed by diagnosis and treatment planning. Typodont exercises include initial level-

ing, cuspid retraction, establishing proper torque, non-extraction treatment, en masse retraction, finishing archwires, upper and four bicuspid extraction treatment, and surgical and non-surgical treatment of severe problems. Laboratory procedures, bonding techniques and marketing are also covered. An 84-page illustrated syllabus is provided.

expectations. He conducts an in-office course designed to provide the orthodontist unfamiliar with concealed braces with the ability and comfort level to start treating lingual cases. The course is also designed to provide an update with the latest advances in lingual mechanics for those already familiar with lingual orthodontics.



Left to right: Drs. Didier Fillion, Courtney Gorman, Kyoto Takemoto and Mario Paz take time for a photo during their Gorman Institute lingual orthodontic seminar presented in Palm Springs in February 1995.

Practicing orthodontists as well as students from all graduate orthodontic programs are encouraged to attend. For additional information or registration contact:
Indiana University School of Dentistry
1121 W. Michigan Street
Indianapolis, IN 46202
(317) 274-7782

Dr. Mario Paz maintains one of the largest lingual orthodontic practices in the United States and is located in an area of high cosmetic consciousness and

A wide range of patients at all stages of treatment is seen, evaluated and discussed by course participants (course is limited to six participants). Lectures, lingual prescription writing, new lingual archwire sequence and mechanics, enamel reproximation techniques, typodont practice and marketing of concealed braces complement the intensive course. Courses are held in April and October each year, with the next course scheduled for October 12-14, 1995. For details, write or contact Shelly at

Dr. Brady

continued from page 9

Dr. Paz's office:
9735 Wilshire Blvd., #308
Beverly Hills, CA 90212
(310) 278-1681

Dr. Kyoto Takemoto presents hands-on typodont courses in lingual orthodontics in his office and in different locations around the world (including courses in collaboration with **Dr. Giuseppe Scuzzo**, prominent international lecturer on lingual orthodontics). Dr. Takemoto's experience in starting approximately 200 lingual cases each year has enabled him to overcome previous technique limitations in treating extraction cases. In fact, his lingual mechanics have achieved treatment advantages over labial therapy in many cases. In the process of space closure with lingual mechanics, special attention must be given to control of the bowing effect and anchorage. Detailed demonstrations for maximum, moderate and minimum anchorage control for lingual extraction cases will be covered using clinical examples.

Four typodont courses are now being scheduled:

- November, 1995, Korea, still in planning stage.
- December 6-7, 1995, Matsudo Main Office, Japan. Contact Nakazawa at Ormco/Sankin, 81-3-3836-2821.
- March 15-17, 1996, Rome, Copresentation with Dr. G. Scuzzo.
- March 28-30, 1996, Spain, Copresentation with Dr. G. Scuzzo. (Contact Dr. Giuseppe Scuzzo in Italy, 39 6 568-5852 for above two courses.)

Lectures by Dr. Takemoto are scheduled for November 19, 1995 (Seoul, Korea, contact Dr. Kim at Ewha Womens University in Seoul, 82-2-650-5196, 7) and November 26, 1995 (Sendai, Japan, contact Nakazawa at Ormco/Sankin, 81-3-3836-2821).

place a regular Ni-Ti™ wire and use vertical interarch elastics to recover arch form. My usual regimen in extreme leveling problems is to use an .016 35°C Copper Ni-Ti archwire in .018 x .025 slots, then use an .016 regular Ni-Ti archwire. A helpful hint in placement of the wire is to apply Endo-Ice®, by Hygenic, with a Q-tip® to the section of wire to be engaged into the extremely unlevel tooth (Figure 3). This technique is especially useful in engagement of rectangular 35°C and 27°C Copper Ni-Ti.

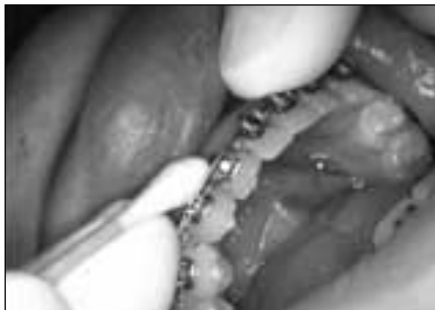

Figure 3. Endo-Ice application facilitates engagement of extremely unlevel teeth.

The second clinical application is that of using a .016 x .022 35°C Copper Ni-Ti sectional wire for retraction of cuspids. Figure 4 shows an adult Class II, Division 2 case in which upper first bicuspids were extracted. A Nance button must be used in this situation to avoid loss of anchorage and molar control. Retraction of the cuspids is done with power chains.

The third clinical illustration is that of decompensation of an adult surgical case that is bonded with ceramic brackets. Figure 5 shows a case where the patient

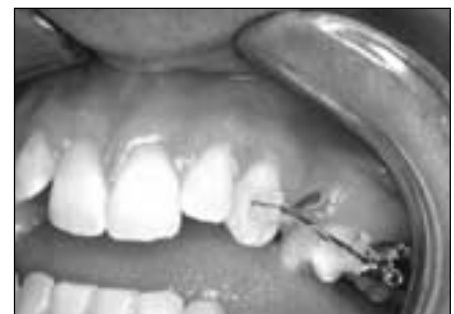
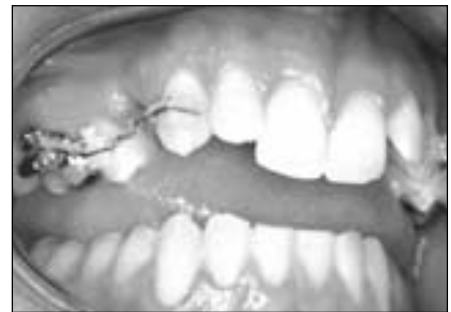
Figure 4. Sectional .016 x .022 35°C Copper Ni-Ti employed in cuspid retraction.

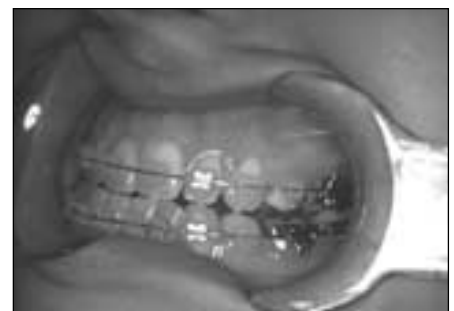
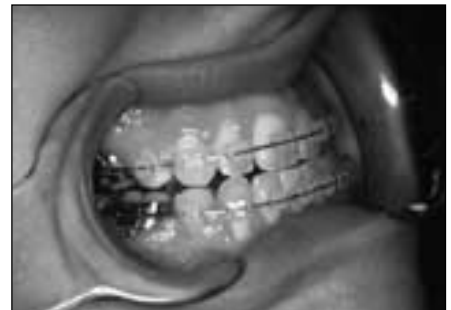
Figure 5. Decompensation of adult surgical case using .016 x .022 35°C Copper Ni-Ti.

was leveled, taken to surgery and finished with the same .016 x .022 35°C Copper
continued on following page

Dr. Brady

continued from preceding page

Ni-Ti wires. The finishing was done by sectioning the wires distal to the cuspid and using vertical up-and-down elastics to "sock in" the occlusion postsurgery. This case had a fairly good pre-ortho fit of the dentition in the hand-articulated study casts. The Ormco Broad Arch form of the upper and lower .016 x .022 35°C Copper Ni-Ti wires placed the canines in good decompensated positions for surgery. Besides rotation, cuspid width was the most important presurgical decompensation in this case. The patient had received orthodontic treatment 10 years previously. She commented several times that she experienced no pain from "tightening the braces." After the first two reties of the rectangular wires with A-2 elastomers, I used tie pliers and .009 or .010 ligature wire for ligation. The ligatures are more effective for rotation correction. I apply Endo-Ice to the Copper Ni-Ti to make the ligation even more effective on more severe rotations. A note of caution: At each retie appointment, check the Copper Ni-Ti wires for kinks or permanent deformations. Run hot water on the 35°C or 27°C Copper Ni-Ti to test for permanent deformation. Place a new wire if needed. This very seldom occurs, however.

A fourth clinical application of Copper Ni-Ti wire is in the periodontally compromised patient. Figure 6 shows a case where the lower incisors were quite loose from periodontal bone loss. In fact, one incisor was extracted for lack of support. Periodontal surgery was done prior to ortho alignment. The initial leveling wires were an .016 35°C Copper Ni-Ti on the lower and an .016 x .022 35°C Copper Ni-Ti on the upper. The patient was instructed to hold hot water in her mouth six times per day for 10 minutes to produce intermittent stronger forces. This wire seemed to be very comfortable for the patient throughout the entire leveling process. It was also noted that the incisors were no more mobile than non-periodontally involved teeth during normal orthodontic movement. Now available is 40°C

Copper Ni-Ti in rectangular sizes to provide intermittent forces *only* when the mouth temperature exceeds 40°C. Used with hot water rinses, it is ideal for periodontally compromised cases or for engagement of severely malposed teeth because of its gentler action. I strongly recommend the use of Copper Ni-Ti wire for patients with periodontal problems.

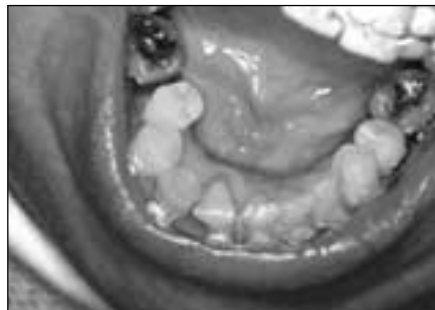
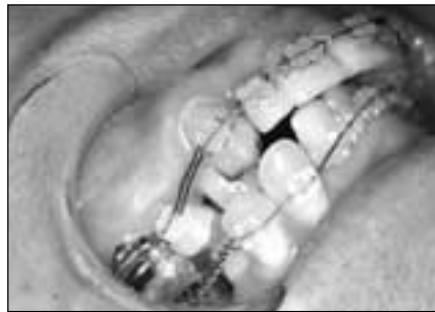
Figure 6. Use of Copper Ni-Ti for initial leveling in periodontally compromised case.

One of the unique applications of this wire is in conjunction with the Herbst appliance. I had the pleasure of taking Dr. Terry Dischinger's "hands-on" Herbst course in his Lake Oswego, Oregon, office. Terry uses .022 x .028 edgewise slots. Figure 7 shows how he utilized .019 x .025 35°C Copper Ni-Ti wire hooked to the upper and lower units of the Herbst appliance. The lower unit of the Herbst is cantilevered from the lower first permanent or lower second deciduous molar. Dr. Dischinger suggests bonding lower incisors with minus 10° torque to prevent flaring. The upper incisors are bonded with the usual torqued and angulated brackets. The engagement of the .019 x .025 35°C Copper Ni-Ti can be

done without permanent deformation or excessive force to the lower incisors, even though the cantilever arm is well below the incisors. Besides stabilizing the Herbst units, it intrudes the lower incisors for bite opening. The upper incisors are engaged using the .019 x .025 35°C Copper Ni-Ti that is attached to the upper-Herbst-unit molar bands. Tie-backs are made on the Copper Ni-Ti wires via pinch-on hooks. The lower wire is always tied back and the upper wire is tied back in cases requiring more orthopedic reaction of the Herbst. The upper wire is not tied back in cases when the distalization of the upper first molars is desired.

The above is a personal review of nitinol and Copper Ni-Ti wires. I truly believe that none of us live in a house that we ourselves have built – we live in a house that others have built. We are fortunate to live there and use its contents for a small amount of time. This is so true of our profession and specifically true for nitinol and Copper Ni-Ti wire. Thanks to Dr. George F. Andreason for making our house more comfortable.

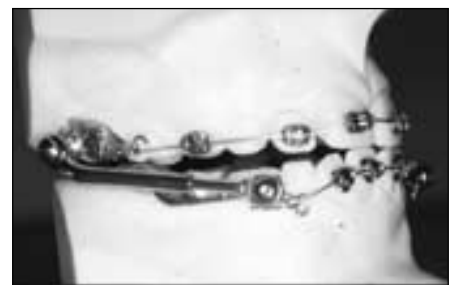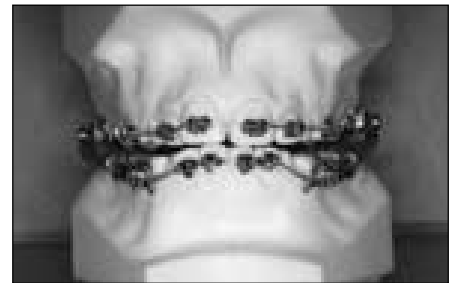


Figure 7. Use of .019 x .025 35°C Copper Ni-Ti in conjunction with Herbst Tx as employed by Dr. Terry Dischinger.

Dr. Swartz

continued from page 17

Copper Ni-Ti™ Selection

Though copper comprises a relatively small percentage of the alloy of Copper Ni-Ti wire, its metallurgical properties allow for an unprecedented precision in setting heat transformation temperatures. Unlike competitive temperature-transformation wires with widely fluctuating, unpredictable activations, Copper Ni-Ti delivers consistent, dependable forces within very narrow temperature ranges.

27° C Superelastic Copper Ni-Ti

Provides unloading (tooth-moving) force comparable to traditional superelastic nickel titanium wires, but is easier to engage because of the lower loading forces built into the copper alloy.

35° C Thermo-Active Copper Ni-Ti

The ideal wire when earlier engagement of full-size wires and sustained unloading forces at body temperature are desired.

40° C Thermo-Active Copper Ni-Ti

Provides intermittent forces (activated only when mouth temperature exceeds 40°C). Ideal for extremely malaligned teeth or for compromised cases requiring caution with force levels. Useful for patients scheduled for long intervals between visits when control of untoward tooth movement is a concern.

Availability: Copper Ni-Ti is available in the Broad Arch Form and the new Orthos™ Arch Form* (both forms in small and large sizes of uppers and lowers).

27°C*: .014, .016, .018, .016 x .022, .017 x .025, .019 x .025

35°C: .016, .018, .016 x .022, .017 x .025, .019 x .025

40°C: .016 x .022, .017 x .025, .019 x .025

For order information on Copper Ni-Ti, see Page D of the Center Section.

*The Orthos Arch Form is not available in 27° Copper Ni-Ti archwires, but is available in traditional superelastic Ni-Ti® archwires.

Bonding to porcelain crowns requires the application of an intermediate silane coupling agent. One end of the silane molecule will react with the silicon in the porcelain and achieve a most tenacious bond. The other end will then copolymerize with the bracket bonding resins.

Ormco's Porcelain Primer contains a dilute solution of the silane in an ethanol carrier. The etching liquid (phosphoric acid) is applied to the porcelain. This simply removes any biofilm present and provides an acidic surface. The primer is then applied with a cotton pellet. The alcohol will displace the water in the etching solution and the silane, in the presence of acid, will chemically bind with the silicon in the porcelain. This reaction takes about one minute. After a minute, rinse the surface thoroughly to remove any excess unreacted silane. Then dry and bond with any of

the bonding materials.

Summary:

- Attention to detail – bracket bonding should not be a relegated duty.
- Rinse thoroughly, a minimum of 5 seconds per tooth with a forceful air/water spray.
- Press the bracket firmly to place.
- Do not move the bracket once the initial gel has begun.
- Leave the bracket undisturbed during the initial set.
- Do not place a load on a new bracket bond.
- Use a plastic primer with polycarbonate brackets or use a new mechanical base plastic bracket.
- Use the gingivally-offset bracket on bicuspids.

Best of success!

...and to liven up your bonding – Wild Spirits*

Conformity can be comfortable but too much can be boring. Wild Spirits will break your practice out of the ordinary. Those wild-spirited type patients who are crazy for colored elastomers will go berserk over Wild Spirits™. A nontoxic luminescent additive makes translucent appliances that are hardly noticeable during the day come alive at night. Typically, brackets will continue to luminesce for up to 10 minutes after being exposed to ordinary incandescent light and can readily be recharged by simply exposing them to a light source.

Present the Wild Spirits option during your consultations and watch your patient starts increase. Wild Spirits may not be for everyone, but everybody will get a kick out of the option, and the wild-at-heart will insist on them. Put the *Rule The Night* patient handout to work for you with prospective patients, current patients and their friends. And put your personal Wild Spirits marketing force to work for

you every night – it's ethical practice marketing at its best.

Wild Spirits feature Ormco's patented MB (mechanical base) bonding pad and all the other outstanding attributes of the Spirit Twin bracket. Wild Spirits are available in twin configuration, in Level Arch Modern (modified Roth) specifications in both .018 and .022 slots. Order information is provided on Page D of the Center Section.



*Patent pending

Lecture/Course Schedule at a Glance – Through December 1995

Date	Lecturer	Location	Sponsor, Contact and Subject
9/15-16	Robin Elledge	Boston, MA	PEP; Christine (800) 854-1741, Ext. 772; "Consultations That Count"
9/18	Mike Swartz	Melbourne, Aust.	U. of Melbourne; J. Doon 612 634 2544; New Archwire Technology
9/20	Mike Swartz	Dunedin, N.Z.	U. of Otago; J. Doon 612 634 2544; New Archwire Technology
9/22-23	James Hilgers	Milan, Italy	Sirio Group; Dr. Arnone 02 204-7610; "The Essence of Practical Orthodontics"
9/25-26	Jorge Calderon	Juarez, Mexico	U.A.C. Juarez; J. Lira 525 264-2125; Adult Orthodontics
9/29-30	Barbara Brunner	Richmond, VA	PEP; Christine (800) 854-1741, Ext. 772; Leadership Seminar
10/3	Jerry Clark	Toronto, Canada	Great Lakes Soc.; Lecture – "It's Not Business as Usual Anymore"
10/6-7	Jorge Calderon	Monterrey, Mexico	U.A. Monterrey; J. Lira 525 264-2125; Class III – Orthopedics, Orthodontics & Surgery
10/12-14	Mario Paz	Beverly Hills, CA	Ormco & Spec. Appli.; Shelly (310) 278-1681; Lingual Orthodontics*
10/13	Barbara Brunner	Detroit, MI	PEP; Christine (800) 854-1741, Ext. 772; Marketing Plans Seminar
10/14	Craig Andreiko	Winnipeg, Manitoba	U. of Manitoba; Dr. Baker (204) 789-3744; "The Orthos Appliance System"
10/19-20	Mike Swartz	St. Petersburg, Russia	Dental Complex; Dr. Voronin 7 812 210 7667; Growth & Dev., Diag. & Tx Plan.
10/20	Robin Elledge	Orlando, FL	PEP; Christine (800) 854-1741, Ext. 772; Patient Relations Seminar
10/21-23	Wick Alexander	Taipei, Taiwan	Yong Chieh; J. Yu (886-2) 778-8315; Alexander Discipline Advanced
10/23-28	J. Hilgers/R. Bennett	Laguna Beach, CA	Drs. Hilgers & Bennett; Linda (714) 830-4101; "The Essence of Practical Orthodontics"*
10/25	Wick Alexander	Hong Kong	FDI Meeting; Lecture – Orthodontic Planning & Tx of Adults
10/26-27	J. Hilgers/R. Bennett	Laguna Beach, CA	Drs. Hilgers & Bennett; Linda (714) 830-4101; Key Personnel Seminar
10/27	M. Scott/M. Payne	Austin, TX	Austin Study Club; Dr. Hime (512) 458-4103; "The Orthos System"
11/2-4	Wick Alexander	Tokyo, Japan	Ormco/Sankin; Nakazawa 81-3-3836-2821; Alexander Discipline Comprehensive*
11/3-5	R. Baker/J. Wildman	Rochester, NY	Eastman Dent. Cent.; Ms. Williams (716) 275-1143; Lingual Ortho. Conference*
11/5-6	Wick Alexander	Tokyo, Japan	Ormco/Sankin; Nakazawa 81-3-3836-2821; Alexander Discipline Advanced
11/7	Wick Alexander	Tokyo, Japan	Alex. Disc. Study Club, Japan; Nakazawa 81-3-3836-2821; Annual Meeting
11/12-13	James Hilgers	Paris, France	AOSM; Josiane (1) 48591617; Basics of Bioprogressive Therapy
11/14	James Hilgers	Paris, France	AOSM; Josiane (1) 48591617; Bio-Orthos System, Non-Compliance Therapy
11/16-18	James Hilgers	Muenster, Germany	U. of Muenster; Ormco GmbH 49 8381 3904; "The Essence of Practical Orthodontics"
11/16-18	Wick Alexander	Arlington, TX	Dr. Alexander; Brenda (817) 275-3233; Alexander Discipline Comprehensive*
11/17-18	Wick Alexander	Arlington, TX	Alex. Disc. Study Club, America; Brenda (817) 275-3234; Semiannual Meeting
11/17-18	R. Elledge/B. Brunner	Glendora, CA	PEP; Christine (800) 854-1741, Ext. 772; Executive Presentations Seminar
11/19	Kyoto Takemoto	Seoul, Korea	Ewha Womens Univ.; Dr. Kim 82-2-650-5196,7; Lecture-Lingual Orthodontics
11/19-21	Didier Fillion	Paris, France	Dr. Fillion; (33) 1-47042793; In-Office Lingual Ortho., Typo. Lab. & Clinic*
11/26	Kyoto Takemoto	Sendai, Japan	Ormco/Sankin; Nakazawa 81-3-3836-2821; Lingual Orthodontics
12/6-7	Kyoto Takemoto	Matsudo, Japan	Dr. Takemoto & Ormco/Sankin; Nakazawa 81-3-3836-2821; Lingual Orthodontics*

*Typodonts and/or Participation

For sponsors' addresses or other course information, call Ormco – Marilyn Van Deroef (800) 854-1741, Ext. 714 or (818) 852-0921. International doctors, please contact your Ormco distributor.

Third Annual Session – The Gorman Institute for Practice Enhancement – Feb. 1-4, 1996

New location – Orlando, Florida. New format – for doctor and staff, focusing on administrative, treatment and human systems to increase effectiveness and efficiency. Mark your calendar now. For a complete program brochure or additional information, contact The Gorman Institute, 4740 Cleveland Heights Blvd., Lakeland, FL 33813, (800) 646-8687, Fax (813) 644-8400.

ORMCO®
A SUBSIDIARY OF
SYBRON
DENTAL SPECIALTIES, INC.

1332 South Lone Hill Avenue
Glendora, CA 91740
(800) 854-1741

BULK RATE
U.S. POSTAGE
PAID
W.M.S.