

CLINICAL Impressions®

PUBLISHED BY ORMCO CORPORATION • VOL. 6, NO. 4, 1997

**Dr. Weinberger On
First Impressions**
Page 2

**Dr. Burk on Copper
Ni-Ti Versatility**
Page 6

**Drs. Epstein,
Mantzikos and Shamus
on Recontouring**
Page 8

**Dr. Bagden on Space
Closure**
Page 14

**Dr. Mayes on the
Frozat**
Page 18

Dr. Weinberger

The New Patient Experience with the Aid of Multimedia

by Gary L. Weinberger, D.D.S., M.Sc.D.
Plainview, New York



Introduction

There is probably nothing more crucial to the vitality of our practices than the experience new patients *perceive* as they are integrated into them. In an era when so much is being challenged with regard to our specialty, it seems appropriate to carefully scrutinize how we can improve our chances of success in communicating our treatment plans to our patients as well as increasing the likelihood patients will be so enthused by the experience that they will refer others. All too often, we leave critical aspects of this interaction to chance, whereas a more careful structuring or “choreography” of the process is far more likely to yield a favorable outcome. Taking advantage of new technologies in combination with refined communications involving all team members in the orthodontic practice has proven to be worthwhile. The goal is to convert essentially every new call successfully. The purpose of this article is to explore how new technologies in combination with good communication skills increase the likelihood of successful conversion.

It may be that “good enough” just *isn't* anymore. In order to attract and retain patients, success may be everything done right, and failure may occur from one thing done wrong. We have, as Peter Drucker mentions in *The New Realities*, evolved from an “information society that has data to a knowledge society that has questions.” The ability of the practice team to provide the answers a consumer-driven society seeks will be a barometer of its success in providing care. And while it is one thing to be aware of the objective, it is quite another to be able to consistently perform the practice objectives on a regular, predictable basis.

Dr. Gary Weinberger received his M.Sc.D. and certificate in orthodontics from Boston University School of Graduate Dentistry. He maintains a private practice in Plainview, New York, on Long Island. Dr. Weinberger also holds a degree in financial planning from Adelphi University and is a sought-after speaker on both management and financial topics.

It follows that effective communication is vital. While the knowledge we need to communicate persuasively and effectively is actually quite basic, some of the best and the brightest don't have it. Whereas a thorough exploration of effective communication is beyond the scope of this discussion, a few basic principles deserve comment:

1. Communication is selling; in this context we are selling a viewpoint. We want our listeners to "buy in" or agree. Perhaps this is best exemplified in the article by my good friend Dr. Keith Black in the last edition of *Clinical Impressions* (Vol. 6, No. 3, 1997).
2. People buy on emotion and justify with fact. While most of us research our decisions, sometimes extensively, most of our major decisions are overwhelmingly influenced at the emotional, preconscious level. We, in effect, decide (or buy) at the emotional level and then use our intellect to justify our decisions.
3. The spoken word is almost the polar opposite of the written word. Written communication is linear, single-channel input. In contrast, spoken communication is multichannel input. In spoken communication, the message we receive is not merely a row of words but also a kaleidoscope of nonverbal cues.
4. In spoken communication, what you say must be believed in order to have impact.
5. Belief is based on trust and is established at the preconscious level.
6. In determining believability, the verbal input (the words we choose) accounts for 7 percent, vocal (intonation, projection and resonance of your voice) accounts for 38 percent, while the visual element (what people see) accounts for 55 percent. When we coordinate these elements, our words have impact. When we send mixed signals, we are not believable. And we must be believable if our presentations are going to succeed.
7. Communication is more effective and learning increases when we use multimedia approaches in our presentations.

The First Contact

It is important to realize that the first contact with our practice is not the initial phone call. It occurs when someone



The receptionist or other designated individual makes the critical first impression a good one.



The NP coordinator assists new patient check-in with an efficient and easy-to-use system.

makes a referral to the practice (almost invariably one exists), creating an initial impression, be it bland or enthusiastic. We need to control this "spin" that individuals place on our practices. On an ongoing basis, the image of the practice is telegraphed to an increasingly discerning public.

The First Phone Call

Much has been written about managing the initial phone call from a new patient (NP), but the reality is that a majority of practices could improve their presenta-

tions. All who are trained to accept NP calls should clearly focus on the goal of the conversation. Although it is important to make an appointment, the far more significant benefit for the practice is to begin building the relationship between the patient and the practice. Accordingly, the person handling the call must not only have refined communication skills but must be willing to spend an appropriate amount of time with the caller. Beyond the obvious basics, it is important for the staff member to promote the prac-

continued on following page

Dr. Weinberger

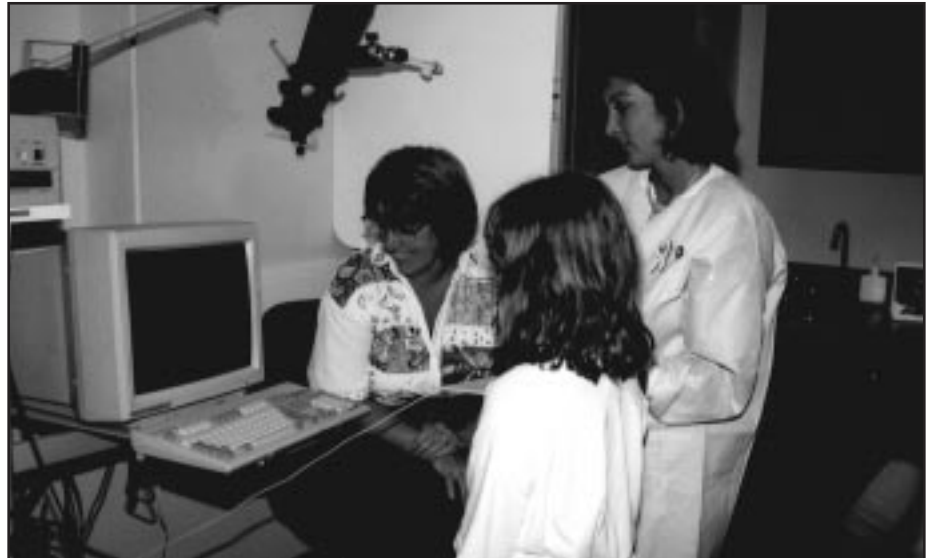continued from preceding page

tice by saying something positive about the doctor and/or practice. As an example, it might be as simply stated as: "I'm anxious for you to meet Dr. Jones. I think you'll find him to be both a wonderful person and equally fine orthodontist." The caller should be acknowledged for taking the first step. Additionally, the staff member should clearly portray in a favorable light what will occur at the first visit. Instead of describing taking molds and X-rays to determine the treatment, I prefer to say, "At the first meeting, we will gather some computer-generated pictures and measurements that will be helpful to Dr. Jones in determining if Jennifer is a candidate for treatment and, if affirmative, when treatment should begin. Dr. Jones will address your concerns and answer all your questions."

It is important that all communication in the practice be framed from the patient's perspective, not in terms of what's good for the practice. Hence, the taking of records, which we would like to do at the first visit if appropriate, is expressed as: "If Dr. Jones feels treatment is indicated and should you desire, records will be taken to clarify the proposed treatment, its timing and its cost." We don't talk about "molds" and "X-rays," because these are negative concepts from the public's perspective. If the caller is an adult patient, the staff member should speak about the large number of adults in the practice and that, if such is the case, a separate area of the facility is set aside for their care.

The First Visit

It can be argued that no aspect of the NP experience is more critical than the first few moments after a patient enters the office for the first time (or even the parking lot). This is because the impression created in the first *two seconds* is so strong that it will take *four minutes* to create an additional 50 percent impression, either positive or negative. Most practices miss a golden opportunity to cultivate the relationship right from the start. It takes a little more time to be polite and show genuine interest in the person, but it pays



The NP coordinator discusses the most obvious aspects of the discrepancy with the patient and parent.

off. Looking at our offices through the eyes of strangers, what do they feel when they walk in? What messages would we like for our facility to communicate?

1. Warm, friendly atmosphere. This is obviously influenced by how the patient is welcomed to the office and everything beyond. The NP coordinator should introduce herself and define her role. Goal: to build a relationship with patient and/or parent.
2. Distinctive and tasteful in its décor.
3. Sparkling and bright, open, encouraging interaction between patient and practice. It should be clear that the practice welcomes its patients' candid comments and suggestions, and does its utmost to answer all questions fully and promptly.
4. Technologically up-to-date or beyond.

It is important to take advantage of multimedia to enhance acceptance. Research has shown that learning is more easily accomplished with visuals (Bert Decker, *You've Got to Be Believed to Be Heard*).

To take advantage, consider the following:

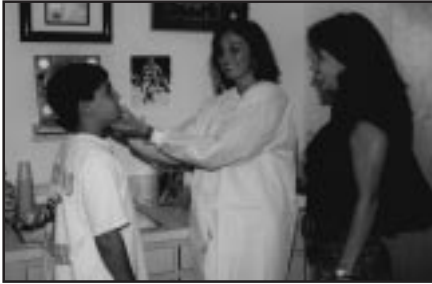1. Written communications: the welcome letter and brochures or other introductory materials. It's not only that you have them, it's what they're about and what they say about the practice.

Are they consistent with the key objectives of the practice, and are they worded with a patient-centered approach? I prefer a brochure with several pictures of the office, the staff and the doctor. We have a unique facility and I want our brochure to speak for the uniqueness of our practice. I have found the Ormco brochure to be effective in this regard.

2. A Web site: Make it interactive and fun, as well as eye catching. Ormco can work with you in developing a Web site.
3. First-visit imaging. Giving patient a copy to take home. This can easily distinguish a practice amongst others, in that it makes it easier for a spouse to explain at home what was expressed by the orthodontist.
4. Automated check-in. Efficient and interactive.
5. The spoken words of the NP coordinator (bright, sunny yellow).
6. The doctor appears: Dress for success.
7. Keeping it light.
8. Incorporating it into one neat package (evolving [or creating] an image).
9. Written patient summary.
10. Follow-up to the one-step consultation.

Knowing that the visual reigns, we should

During the visit, the NP coordinator demonstrates the friendly, caring nature of the practice while:



A. covering proper technique at the brushing center.



B. viewing the bulletin board's display of a potpourri of happenings and patient activities.



C. showing the easel announcing contests, new movies, past contest winners, etc.



D. pointing out the mini TVs used for entertainment and multimedia education.

use this information in combination with refined vocal and verbal choreography to

enhance our presentations. One approach is to use imaging technology. We use the Dolphin system, which provides a great "take-home" picture for us.

Using the aforementioned principles, we might structure the first visit as follows: The receptionist or other designated individual greets the patient just as we would welcome a guest into our home. This individual then introduces the patient (and parent, if the patient is a child) to the NP coordinator, if the practice utilizes this concept. I feel that a designated person to integrate new patients into the practice is an effective mechanism for introducing them. We use the Orthotrac automated check-in system, which I have found to be both efficient and well accepted by patients. Of course, at the first visit the patient is assisted in checking in.

This individual explains her role to the prospective patient and parent. She then explains that she is going to take some computer-generated pictures, using new technologies, that will be helpful in seeing the teeth and facial features. She points out that this is a completely noninvasive procedure and not uncomfortable in any way, and that once these photos and measurements are gathered (which will take about 10-15 minutes), the parent will meet with the doctor to discuss the findings. Under some circumstances, it may be appropriate to seek permission to take a panoramic film at this point; however, this may best be deferred until after the parent meets the doctor.

In the one-on-one with the patient, in addition to gathering the essential information, the NP coordinator can make an assessment as to the patient's disposition toward treatment, concerns, etc., and most importantly, build rapport. A skilled individual will not only gather the appropriate information but will also put the patient at ease in the process.

Once this information is obtained, the NP coordinator escorts the parent into the records room. The staff member will then

point out the likely conditions the doctor will discuss; e.g., an overbite, crossbite, etc. This is best described as a "planting the seed" approach, again, with the choice of words – not to mention the delivery – being most critical. As an example, in describing an overbite, the NP coordinator might refer to the picture showing the overbite, merely point out how the upper teeth overlap the lowers and say, "I'll bet the doctor will talk about that." Or, in visualizing the crowding, she might indicate, "You see how those teeth don't seem to have any room? I'll bet Dr. Weinberger brings that to your attention." The purpose of this short but effective interaction is for the parent to gain a sense of professionalism about the office and its staff, as well as for the practice to take advantage of the greater degree of credibility of a staff member who does not have a vested interest (in the eyes of the parent) in communicating the problem. Subsequently, the doctor's input will have more impact. Additionally, the NP coordinator can make an appraisal of the patient and parent as a "1," "2" or "3," our designations regarding the easiest as opposed to the most difficult situation in presenting the case. Thus, prior to seeing the doctor, the patient has some feedback regarding the orthodontic disposition and a sense of comfort regarding the practice. The doctor has pertinent information from the NP coordinator's interaction as well as the information provided by a well-conceived history form. In other words, we have dramatically increased the probability of an effective presentation. The NP coordinator then asks the doctor to come in and introduces him to the patient and parent.

The doctor's first priority, as is every other team member's in this initial visit, is to establish rapport. This can be done in any number of ways. I find it quite easy to reference the photos, point out what a great patient they must be to get such star-quality photos, and compliment the staff member on her good work as well. This again builds the esteem of the practice from the patient's perspective. It is

continued on page 22

Creative Use of Copper Ni-Ti



by Dr. Saul Burk, D.D.S., M.S.
Gaithersburg, Maryland

Copper Ni-Ti™ is a new quaternary alloy (nickel, titanium, copper and chromium) with distinct advantages:

1. Constant force over long activation spans
2. Near constant force guaranteed
3. Resistant to deformation

4. Less drop in unloading force
5. A thermal treatment process that produces three different transformation temperatures: 27°C, 35°C and 40°C.

The low load-deflection characteristics in conjunction with resistance to permanent deformation provide a large range of activation. These properties allow creative use of Copper Ni-Ti. The illustrations show how Copper Ni-Ti can be placed above and below orthodontic brackets to institute intrusion or extrusion of teeth.

The most common use is to level the mandibular plane of occlusion by placing the wire to the incisal of the mandibular anterior brackets or to the gingival of the first and second bicuspid brackets. If you are concerned with rotation of these teeth, place a sectional wire in the bypass segment. I have also used this technique to open bites by placing the Copper Ni-Ti wire to the incisal of the maxillary or mandibular anterior brackets.

An anterior open bite can be closed by placing the wire to the gingival of the maxillary anterior brackets and/or the mandibular anterior brackets. Vertical elastics may be used but are generally not necessary.

Another use is to weave this wire above or below an orthodontic bracket that could not be ideally placed initially. This technique will compensate for a bracket height discrepancy. I have found that an .016 35°C or .016 x .022 35°C wire works very efficiently over 10-12 weeks. I have used other wires, but our patients seem to prefer the gentle action and I am very pleased with the results obtained with Copper Ni-Ti.

Dr. Saul Burk received his D.D.S. from the University of Maryland and his M.S. and certificate in orthodontics from Georgetown University. He was an assistant professor of orthodontics at Georgetown University for 11 years. Dr. Burk is in private practice in Gaithersburg and Olney, Maryland.

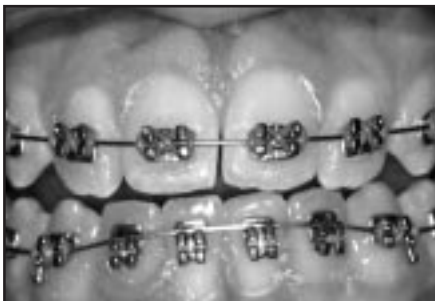

Figure 1A. The mandibular anteriors are being intruded using an .016 x .022 35°C Copper Ni-Ti placed to the incisal of the anterior brackets.

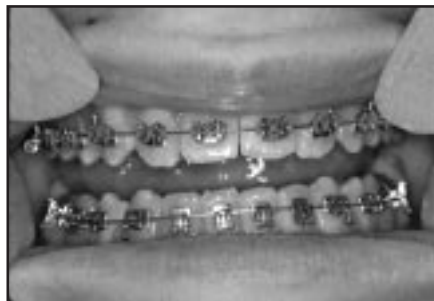

Figure 1B. The mandibular anteriors intruded after ten weeks.

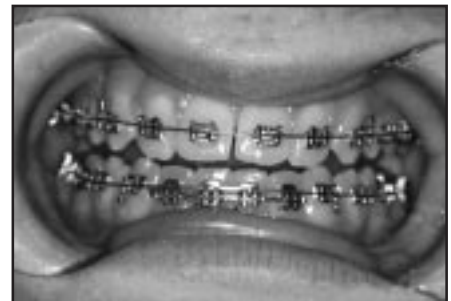

Figure 1C. An .019 x .025 Force 9® sectional is placed to level the anteriors

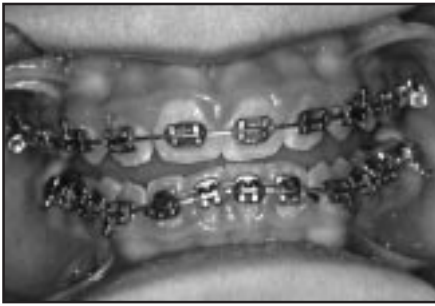

Figure 2A. The mandibular anteriors are being intruded with an .016 35°C Copper Ni-Ti placed to the incisal of the brackets. Notice that a bypass .016 x .022 35°C Copper Ni-Ti is leveling the anteriors.

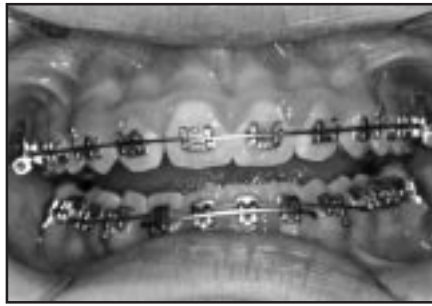


Figure 2B. Ten weeks later, notice the intrusion of the mandibular anteriors and the leveling effects of the bypass sectional.

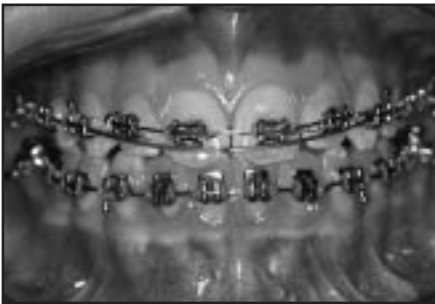

Figure 3A. The maxillary anteriors are being intruded using an .016 x .025 35°C Copper Ni-Ti. An .017 x .025 TMA® stepped down in the mandibular anterior region has been placed after the mandibular anteriors have been intruded.

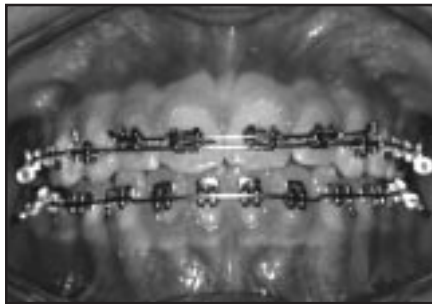


Figure 3B. Intrusion of the maxillary anteriors after ten weeks.

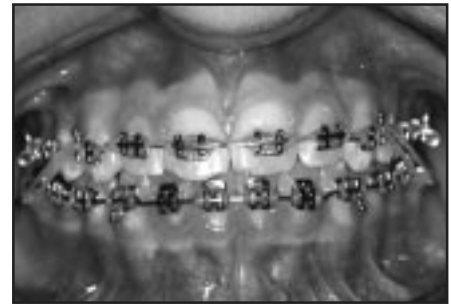


Figure 3C. Maxillary .017 x .025 TMA stepped up in the maxillary anterior region. Class II elastics (Ormco Fox) are placed.

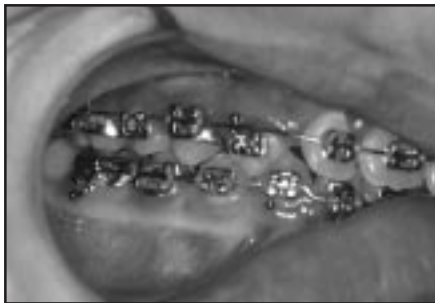

Figure 4. Extrusion of the maxillary second bicuspid and cuspid.

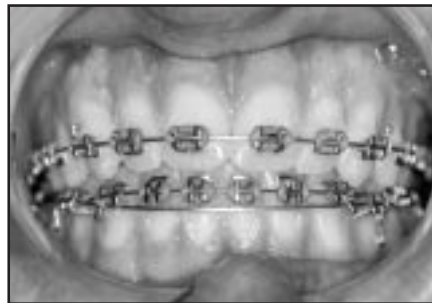

Figure 5. Closing an open bite using an .016 x .025 35°C Copper Ni-Ti to the gingival of the mandibular cuspid and anterior brackets. An anterior bypass wire was placed from cuspid to cuspid.

Copper Ni-Ti™ Line Extended in Answer to Your Requests

Copper Ni-Ti is playing a leading role in the specialty's transition from cross-sectional archwire mechanics to variable modulus. The many benefits, including earlier rectangular archwire engagement, increased intervals between patient visits, reduced treatment times and increased patient comfort, all add up to increased practice efficiency and profitability. As the use of Copper Ni-Ti has grown around the world, we've been expanding the line in response to your requests. Take a look at and take advantage of our growing family of Copper Ni-Ti

archwires. Order information is provided on page D of the Center Section.

Current Copper Ni-Ti archwire availability (more recent introductions bolded):

Available in both Orthos™* and Broad Arch forms –

27° – .014,**.016,**.018, .016 x .022,**.017 x .025,**.019 x .025**
35° – .016, .018, .016 x .022, **.017 x .017**, .017 x .025, .019 x .025,
.020 x .020, .021 x .025

40° – .016 x .022, .017 x .025, .019 x .025, **.021 x .025**

Dimpled midpoint (to prevent creep) Orthos form archwires –
.018 (27°), .016 x .022 (35°), .019 x .025 (35°)

*Products identified as "Orthos" are distributed in Europe as "Orthos-CIS"

**Available in Broad Arch form only

Esthetic Recontouring of the Orthodontically Treated Occlusion

by **Martin B. Epstein, D.D.S.**
New York, New York
Theo Mantzikos, D.M.D.
New York, New York
Ilan L. Shamus, D.D.S.
New York, New York

The increasing demand for cosmetic orthodontics has led to advances in the art of esthetic recontouring. The presence of irregular incisal edges, a worn or abraded dentition and imbalances in tooth morphology may limit our ability to produce a cosmetic result. These features may

detract from the well-treated orthodontic alignment.

Esthetic Recontouring

Recontouring of teeth by grinding may be indicated in conjunction with orthodontic treatment. Esthetic recontouring is the process of selectively remodeling teeth to affect their shape, position, length, contour and proximal relationship with adjacent teeth. Youthful, feminine smiles are typically characterized by rounded incisal edges, open incisal and facial embrasures and softened facial line angles.


In a more masculine smile or one characteristic of an older individual, incisal embrasures are more closed and incisal angles more prominent. Significant generalized changes are possible when treating all anterior teeth visible in the patient's smile. The composition of the smile is primarily characterized by the architecture of the maxillary anterior teeth. The mandibular anterior teeth may also play a defining role (Figures 1A-D). Cosmetic orthodontics is an art form and its treatment objectives necessitate specific guidelines in order to achieve the desired



Dr. Martin Epstein serves as assistant clinical professor at New York University College of Dentistry, Department of Orthodontics and on the attending orthodontic teaching staff at Staten Island University Hospital. He is engaged in the private practice of orthodontics in New York City and Staten Island, New York.



Dr. Theo Mantzikos is an assistant clinical professor at New York University College of Dentistry, Department of Orthodontics and Department of Oral Implantology. His private practice of orthodontics is located in New York City.



Dr. Ilan Shamus is an assistant clinical professor at New York University College of Dentistry, Department of Orthodontics. His private practice of orthodontics is located in New York City.

esthetic and functional result. The following eight considerations facilitate the decision process in the shaping and recontouring of enamel:

Horizontal Components

- *Smile form* – The horizontal curvature of the outline of the maxillary incisal edges and lower lip (Figure 2A).
- *Gingival margin harmony* – The maxillary central incisor gingival margins should be 1mm apical to those of the lateral incisors. The gingival margins of the canines and centrals should be at approximately the same level (Figure 2B).
- *Incisal edge balance* – Maxillary central incisors and canines are positioned the same vertically and the lateral incisors are slightly shorter both cervically and incisally.
- *Embrasure form* – The form is influenced by the morphology of the teeth, their widths and their arrangement.

Vertical Components

- *Maxillary midline* – A coincidence of dental and facial midlines establishes a vertical reference line for symmetry and balance between the two halves of the smile (Figure 3A).
- *Smile foundation* – The maxillary central incisors serve as the key to the smile. A 3:4 width-to-length ratio is ideal.
- *Axial alignment* – Mesial inclination of anterior teeth tends to be pronounced from central incisor, to lateral incisor, to canine.
- *Golden Proportion* – The widths of maxillary anterior teeth correlate. From a frontal view, the curvature of the smile has each tooth displaying 60 percent of the size of the tooth immediately anterior to it (Figure 3B).

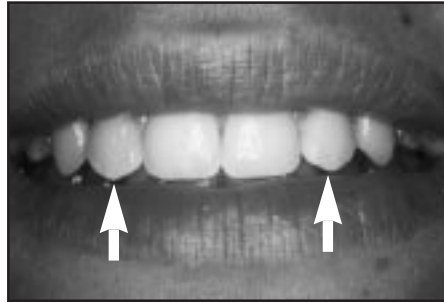
Technique

Cosmetic Preview

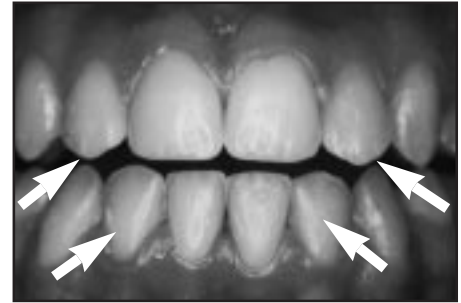
Initially, determine if the completed orthodontic result could be improved with recontouring. Anterior guidance, canine guidance and group function must be assessed and maintained prior to the initiation of conservative remodeling procedures. Patients with open-bite tendencies or vertical discrepancies must be treated carefully, especially if they have short, abraded teeth. Teeth that have been restored either by crowns or large fillings

continued on following page

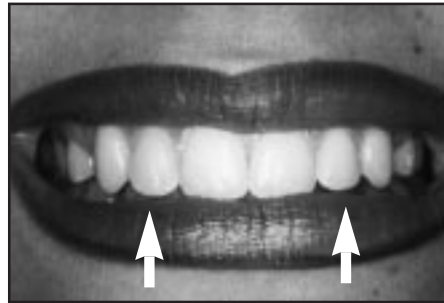
Figure 1. Improving the smile by recontouring:



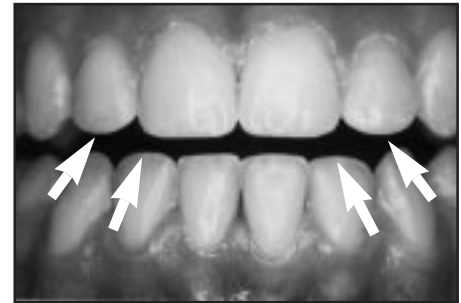
1A. Smile form displaying incisal edges of maxillary anteriors.



1B. Preexisting anterior teeth.

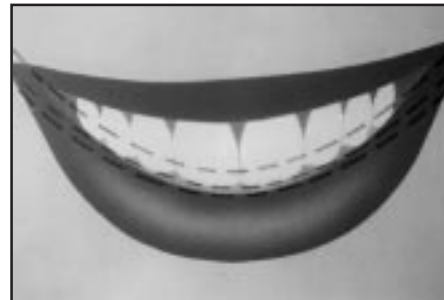

1C. Completed recontouring of smile form.




1D. Anteriors with esthetic recontouring completed.

Figure 2. Horizontal components of the smile:

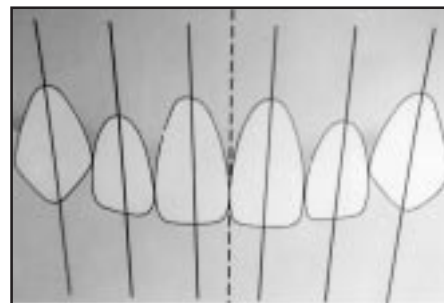


2A. Smile form and incisal edge balance.

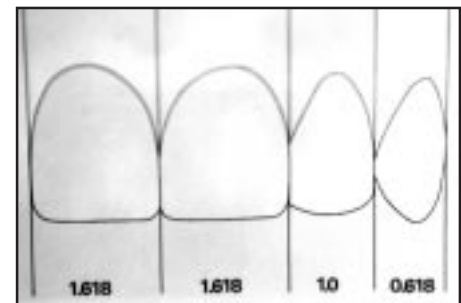


2B. Gingival margin harmony and embrasure form.

Figure 3. Vertical components of the smile:



3A. Maxillary midline, smile foundation and axial alignment.



3B. Golden proportion.

continued from preceding page

must be taken into account prior to esthetic recontouring. Periodontally compromised teeth and teeth with fixed prostheses pose difficult treatment limitations. Gingival inflammation and poor oral hygiene are also limiting factors.

Preparation Design

Esthetic recontouring is not meant to be a substitute for incomplete treatment. The prime tenet of recontouring is the preservation of tooth structure.

Once the treatment plan is selected, the teeth must be adequately and conservatively prepared. The best preparation is determined on an individual basis for each given clinical situation. The shape and form of the teeth largely determine the esthetic appearance. It is imperative that natural, anatomic forms be achieved in order to obtain optimal results. Although exceptions to the guidelines presented will arise, the scheme is intended to provide the clinician with a working guide that can be considered in esthetic recontouring. The use of a high-speed handpiece, a generous water supply and light, intermittent brush strokes is recommended for recontouring.

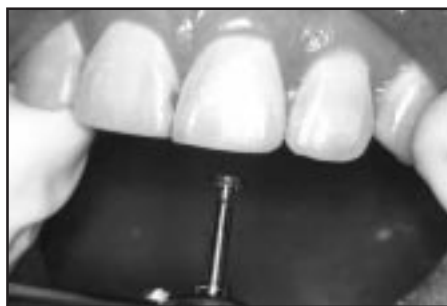Step-by-Step Procedure

Step One: Incisal Reduction – Starting with the maxillary central incisors, recontour the incisal surfaces to make them mirror images of one another (Figure 4). Next, prepare the maxillary lateral incisors and canines using similar procedures. Incisal surfaces should be prepared judiciously. Merely flattening the incisal surface results in excessive loss of tooth structure.

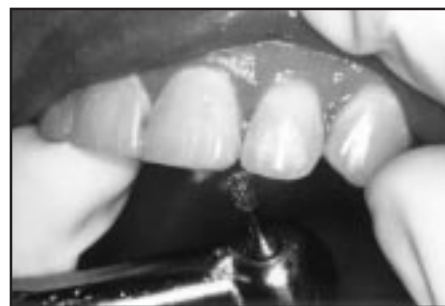Step Two: Distal Shaping – Starting with the maxillary central incisors, reshape the disto-incisal corners of both teeth (Figure 5). This results in central incisors that are mirror images of one another. Prepare the lateral incisors using the same procedures (Figures 6A-B).

Step Three: Mesial Shaping – Reshape the mesio-incisal corners of both maxillary central incisors. This will result

Figures 4 and 5. Reduction and shaping:

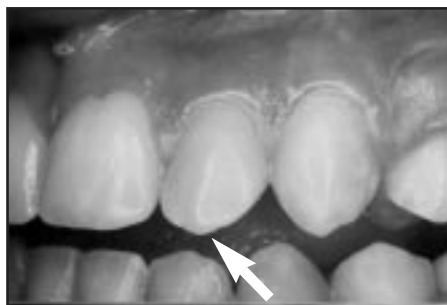

4. Diamond wheel used parallel to the incisal surface of the tooth.

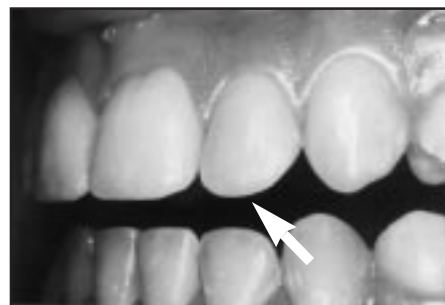

5. Diamond football used perpendicular to axial inclination of the tooth.

Figure 6. Recontouring lateral incisors:

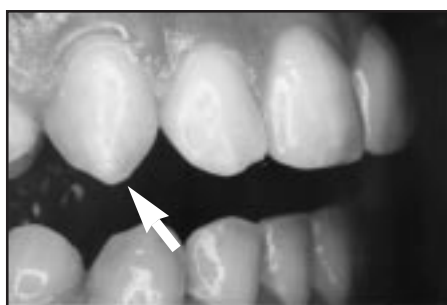

6A. Note preexisting maxillary lateral incisor shape.

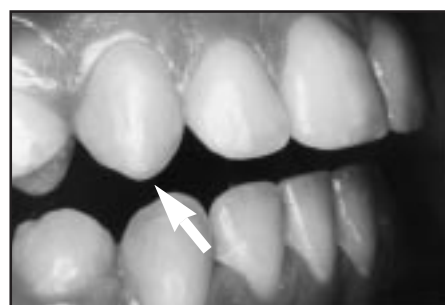

6B. Completed esthetic recontouring.

Figure 7. Recontouring canines:

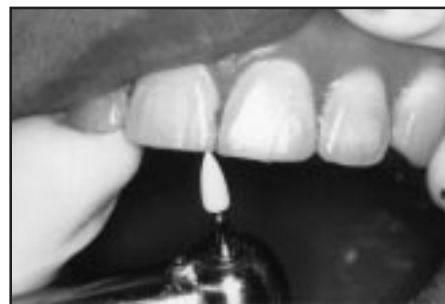

7A. Note preexisting maxillary canine shape.



7B. Completed conservative esthetic recontouring.

Figure 8. Gross polishing:



8. Mounted white stone used for gross polishing of recontoured surfaces.

in two symmetrical teeth. Prepare the lateral incisors in similar fashion. Maneuver the fine-point diamond perpendicular to the mesio-incisal margins of the teeth.

Step Four: Labiolingual Reduction – Contour any sharp corners or edges remaining as a result of incisal reduction and mesiodistal recontouring. Special attention must be paid to the lingual edges, labiolingual dimensions and incisal edge thicknesses. Use a football-shaped diamond bur for this procedure.

Step Five: Canine Shaping – The preparation of the maxillary canines is determined by anterior esthetics and occlusal

interrelationships. Incisal reduction of cusp height has previously been completed in relation to the central and lateral incisors (**Step One**). The mesial and distal incisal surfaces should be prepared with the mesial slope being the shorter of the two and corresponding to the natural anatomy of the tooth (Figures 7A-B). This results in canines that are mirror images of one another. A football-shaped diamond bur is also used for this procedure.

Step Six: Final Assessment – An evaluation of the esthetics and function should be done to critically determine if recontouring objectives have been met. Smooth

and polish at the end of the adjustment to reduce heat and trauma to the teeth.

Step Seven: Gross Polishing – Mounted white stones are used across the prepared surfaces (Figure 8). Start with coarse sandpaper discs and gradually work toward ultrafine discs.

Step Eight: Fine Polishing – Add a final luster with fine pumice or polishing paste in a prophy cup.

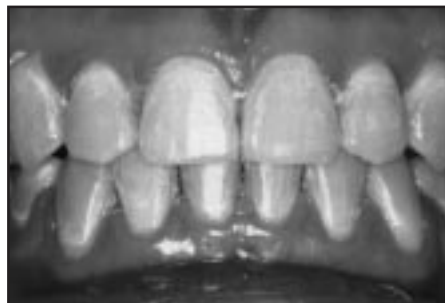Step Nine: Fluoride Treatment – Following the recontouring, perform a topical fluoride treatment on the prepared surfaces.

Case Reports

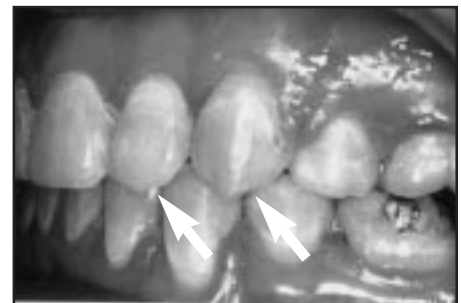
Case #1

A 30-year-old female is shown after having just completed orthodontic treatment for a Class I crowded malocclusion (Figures 9A-B). The composition of her smile was not harmonious. Recontouring was recommended to provide a more esthetic appearance to the maxillary anterior teeth. Special consideration was given to the maxillary lateral incisors to benefit the final cosmetic result. Evaluating before-and-after photographs via the guidelines suggested, one visualizes the esthetic improvement (Figures 10A-C).

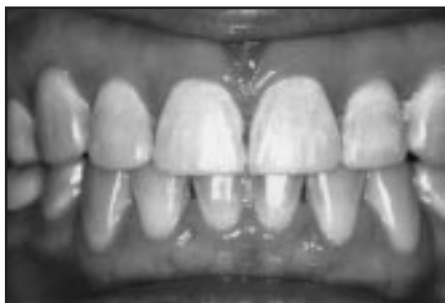Figures 9 and 10: Case #1



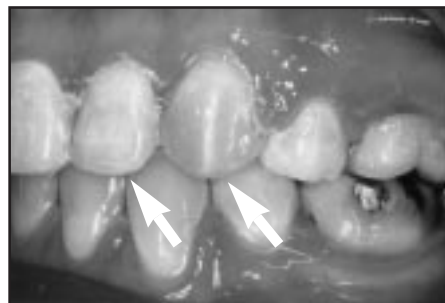9A. After appliance removal and prior to recontouring.



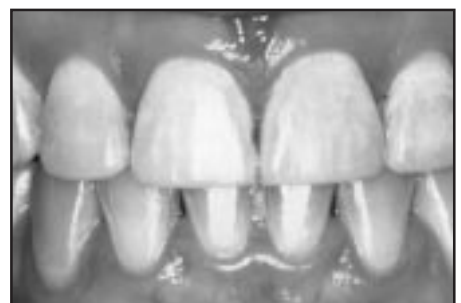9B. Lateral view showing need for lateral and canine recontouring .



10A. After recontouring.



10B. Lateral view showing reshaped lateral and canine.



10C. Close-up view showing final esthetics.

Case Reports

Case #2

A 28-year-old male is shown after completing orthodontic treatment for a mutilated, Class II, division 1 malocclusion with significantly worn and abraded maxillary anterior teeth (Figure 11A). Discrepancies can be identified at the incisal edges of the central and lateral incisors. Furthermore, there is no continuity to the mesio-incisal and disto-incisal edges. The necessity for esthetic recontouring was justified after reviewing the esthetic guidelines. A more balanced smile has been achieved following the procedure, adding to the successful orthodontic treatment (Figure 11B).

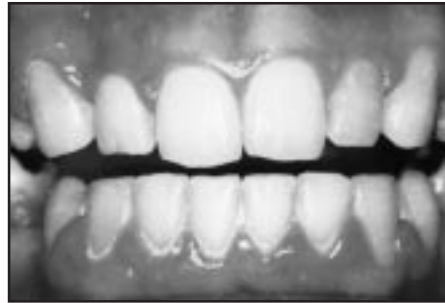
Case #3

Occasionally, reshaping of the mandibular incisors is recommended. Recontouring of jagged mesial and distal incisal angles may be required. The incisal surface should be prepared at a right angle to the long axis of the tooth. This patient presented with unesthetic incisors and a periodontal defect. Treatment planning included a periodontal grafting procedure and incisal recontouring (Figures 12A-B).

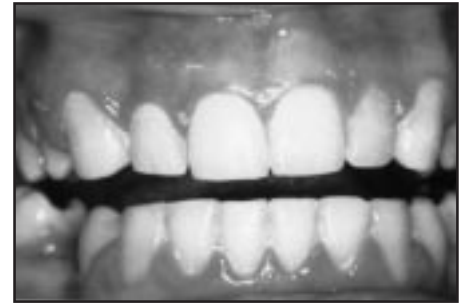Conclusion

Specific details of tooth positioning and intentional changes in tooth morphology by recontouring can significantly improve the final occlusal and esthetic result. The concepts and guidelines suggested to facilitate the decision to produce an esthetic orthodontic smile have been outlined and demonstrated through case presentations.

Figure 11. Case #2:

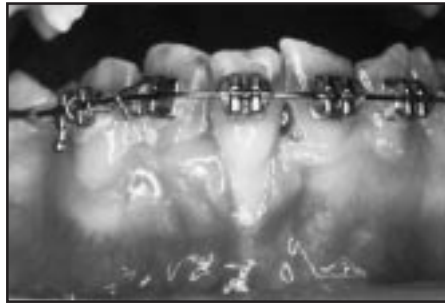


11A. Orthodontic result prior to recontouring.

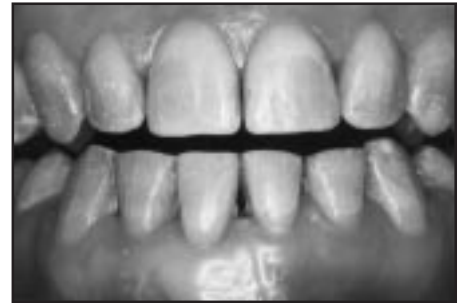

11B. Completed esthetic recontouring.

Figure 12. Case #3:



12A. Preexisting mandibular incisors during treatment.



12B. Completed recontouring & periodontal graft of incisor area.



Hiring: Sleuth's Work

by Barbara Brunner, M.A., Orange, California

The business section of your local Borders or Waldenbooks is rife with literature about how to hire qualified staff members. Most of the literature is geared to the corporate culture, where promising resumes need to be culled from the dozens received for any particular position. For the average orthodontist, especially those outside major metropolitan areas, job applicants are sparse and may not recognize the need to develop a resume. If they do, it may entail a listing of job titles with little to no mention of duties or accomplishments. In other words, you'll need to do more detective work to ascertain a candidate's appropriateness for your practice. To make the exercise manageable, seek abilities that consist of two components: skills (or the ability to develop the skills) and fit (the ability to assimilate easily into the culture of your particular practice).

One of the best ways to determine the types of attributes and related abilities that you're looking for through your questions is to ask your most effective staff members to answer them. You may not often be in a position to see a direct link between the abilities you seek and the candidate's experience. Becoming your own detective can result in hiring successful staff members even when the applicants do not immediately seem to meet your needs.

Hiring is a major segment of a course entitled "Round Peg...Round Hole" that Ms. Janette Piankoff and Ms. Barbara Brunner are conducting in 1998. For more information about this course, contact Katie Morrissey (800-854-1741, Ext. 7573). Ms. Brunner is manager of Ormco's Practice Development Seminar Series. Ms. Piankoff is the hiring and training specialist for Sybron Dental Specialties and has developed many of the ideas presented in this article.

The Gumshoe's Guide to Skill Detection

Let's look at the position of clinical assistant. Let's say that no candidate from whom you receive an application has any dental or orthodontic experience, nor have any attended a technical school. So how do we ferret out whether the candidate is likely to be able to develop the skills you need? First, develop a listing of required abilities that would lend themselves to success in this position. Since there is no direct link between these abilities and the actual experience of any of the candidates, look for related abilities and skills the candidate may have that would be a good indicator of the candidate's capacity to develop the skills. From these, design questions that could help the candidate identify those abilities for you.

Abilities: Clinical Skills

Manual dexterity enabling candidate to assist with or conduct orthodontic procedures.

Ability to follow detailed instructions.

Ability to communicate procedures to patients and to put patients at ease.

Type Questions to Ask

This position requires the ability to work well with your hands in a small space. Give me some examples of things you have fixed or things you tinker with that demonstrate this ability.

Give me examples of times you had to follow detailed instructions in order to be successful.

Give me examples of times you have given instructions to other people. Share with me some of the phrasing you have used. Tell me about a time you had to calm someone.

Examples of Related Abilities/Skills

General "fix-it" orientation: bike chain, lawnmower, toy assembly. Hobbies or jobs requiring fine motor skills: sewing, needlepoint, pottery, electronic gadgetry. A summer job at Cloth World may indicate a good match.

Administrative work in a bank, insurance or other office. Serving as treasurer for a club. Cashier, order entry, reservationist.

Volunteer work in a hospital, church, or "Y" program where the applicant is not the boss but is serving in a helper role. Look for clear, direct instructions from a coaching orientation.

Agatha Christie's Course on Cultural Fit

Besides specific skills or the ability to develop specific skills, you're also looking for personality fit with your practice. Is yours the type of practice where people pitch in without hesitation to help fellow staffers? Then you want to ensure that the candidate is open to that kind of flexibility. Bullet point the most salient aspects of your culture. Translate those aspects into questions and develop some examples of the types of attributes that meet your cultural fit requirements.

Abilities: Cultural Aspects

Ability to handle multiple tasks simultaneously, maintaining high clinical standards within a tight, high-volume appointment schedule.

Ability to handle various personalities.

Ability to work as part of a team and to help out in all parts of the practice.

Type Questions to Ask

What do you do when you have several important tasks to be completed within a short time? Give me an example of a time when you had to make a decision without having all the direction you felt you needed from your manager or teacher.

Tell me about a manager or teacher who annoyed you and how you dealt with them. Tell me about a situation in the past year in which you have had to deal with an upset customer or classmate.

What did you do in your last job or at school to contribute toward a team environment? Give an example of a time when you had to go above and beyond the call of duty to get the job done.


Examples of Cultural Attributes

Ability to establish priorities, remain calm, keep sense of humor under pressure. Ability to work independently, yet show team play.

Ability to manage and own their emotions. Ability to engage another in resolving a misunderstanding or problem. Willingness to take at least partial blame for a conflict.

Flexibility in assisting others. Willingness to see the overall success of the practice as part of their job.

Space Closure in the Age of “Variable Modulus” Mechanics



by M. Alan Bagden, D.M.D.
Springfield, Virginia

A truism of life is: “The more things change, the more they remain the same.” The same, certainly, holds true for orthodontics. For as much as we believe we are revolutionizing the specialty, we are only modifying and *improving* that which we have seen in earlier years. An example of this can be seen in the process of space closure.

Nothing could be more basic to our science than the control of space. Quite simply, in order to align teeth, we are first concerned with making enough space to fit them all in, then we close what is left over after we have aligned them. One can easily picture the orthodontic pioneers wrestling with this problem, much as we do today. The only difference is that we have more options today, options as to techniques, metals, forces and desired side

effects. When all are considered, however, the Reverse Curve TMA® with “T” Loops (TMA “T” Loop) is one of the most versatile multipurpose archwires available. Understanding the uses, limitations, applications and anticipated actions of this wire can only improve its value to any practitioner, for this one wire can offer tremendous efficiency of time and force utilization.

History

If one were to study the genealogy of the TMA “T” Loop archwire, it would be found to have its roots firmly planted in a popular technique of the mid-seventies – the Broussard two-force technique. For it was in the writings explaining this philosophy that the combination loop archwire (CLA) was described (Figure 1).

The authors cite many uses of the CLA:

1. to open or close spaces
2. to elevate or depress anterior or posterior teeth

Dr. M. Alan Bagden, currently practicing in Springfield, Virginia, received his dental medicine degree from the University of Pennsylvania School of Dental Medicine and his orthodontic training from the University of Maryland. A diplomate of the American Board of Orthodontics and a fellow of the American College of Dentists, Dr. Bagden is a past president of the Northern Virginia Dental Society and is president-elect of the Virginia Association of Orthodontists. As an advocate of economical and time-efficient orthodontic treatment, Dr. Bagden has a special interest in clinically evaluating new and progressive orthodontic products.



Figure 1. Combination loop archwire with “whipped in” reverse curve.




Figure 2. TMA “T” Loop (not activated).




Figure 3. TMA "T" Loop with anterior step-up to facilitate bite opening.




Figure 4. Preactivated "T" Loop, as prescribed by Hilgers, to be used to advance and intrude laterals in a Class II, division 2 case.



Figure 5. Anterior gabbling torque placed at the anterior vertical step. It can be added with an optical plier.

3. to open or close the bite
4. to level the curve of Spee
5. to engage Class I, II, III or up-and-down elastics
6. to torque the anterior or posterior teeth
7. to attach J-hooks for a headgear in retracting the anterior teeth

Great care was taken to explain the construction of this wire, emphasizing that the posterior parts of the CLA wires should be "whipped" into a reverse curve of Spee. Slight lingual root torque was placed in the anterior section.

The TMA "T" Loop is the natural and logical evolution of this very efficient archwire. What has been afforded us are the benefits of continued advances in wire technology. All that is good about the CLA is still there, but by incorporating TMA properties and answering current treatment demands, the CLA has evolved into a superior product for contemporary orthodontic treatment.

Pertinent Properties

The advent of titanium molybdenum alloy (TMA) has brought about a host of positive changes to the venue of orthodontic treatment. TMA is actually an alloy of four metals:

Titanium	78.0%
Molybdenum	11.5%
Zirconium	6.0%
Tin	4.5%

Unlike many other archwires, it contains no nickel and is therefore well tolerated by patients sensitive to nickel. Through the developments resulting from the work of Burstone, Swartz and Hilgers, this alloy has become a staple of contemporary orthodontic practice.

Burstone summarized the unique properties of TMA and its appropriate applications in the early 1980s. He found TMA to be useful where low forces and superior formability, ductility and springback are desired. It is a good leveling arch because its springback is twice that of stainless steel (where there is a great discrepancy between bracket heights, Copper Ni-Ti™ is now the wire of choice). TMA can be shaped, can hold required bends and can hold the "whipping" needed to place a reverse curve of Spee.

Swartz also recognized the value of TMA and advocated specific uses in orthodontic practices. He felt that the relatively reduced stiffness of TMA versus conventional stainless steel (TMA is 42 percent as stiff), coupled with better than twice the resiliency, made it possible to use larger rectangular wires earlier in treatment, with the advantage of increased torque. Its extended plastic range and formability into loops and bends suggested that it was an ideal choice for early-in-treatment utility arches. Bendability is a key to TMA's success. It is rarely broken during forming, inserting or activating.

Hilgers, through development with Ormco in the early 1990s, synthesized all the previous information and developed the TMA "T" Loop archwires to achieve simultaneous opening of the bite with anterior space closure. It truly is a natural progression from the original Broussard CLA wire, enhanced through the metallurgical developments of the 1980s. Almost ten years after its inception, the TMA "T" Loop wire is an integral part of many orthodontic practices, performing numerous functions.

Wire Progression

In our practice, the TMA "T" Loop wire is typically used following initial leveling and aligning with Copper Ni-Ti rectangular wire. Since we follow the Alexander Discipline, our slot size is .018 x .025. The initial Copper Ni-Ti archwire is either .016 x .022 or .017 x .025, depending on the degree of crowding, which influences how fully we can engage the wire in the slots. Now, in the course of early leveling, bite opening can be initiated with either a bite plate or utility arches, if necessary. But it is at this point, when retraction is complete and space closure is about to commence, that the TMA "T" Loop wire is truly a superior choice, performing multiple functions simultaneously.

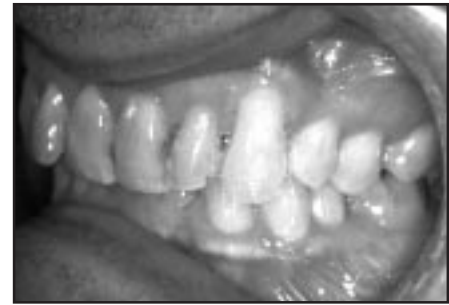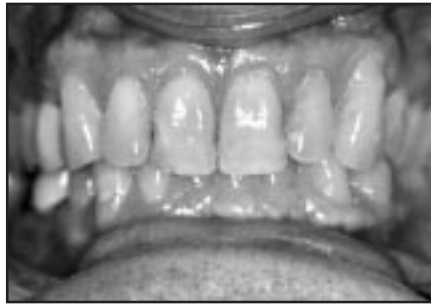Clinical Applications

Figure 2 shows the "T" Loop wire as it presents preformed and ready to use in its simplest form. Figure 3 shows the wire with an anterior step-up that is very useful in deep-bite cases to intrude the anterior segment while retraction is occurring. This anterior step-up complements the reverse curve action of the wire, which in turn facilitates bite opening to a greater degree than the simple wire in Figure 2. Figure 4 shows the "T" Loop preactivated at the top of the loop and ready for insertion, as prescribed by Hilgers. This particular activation is extremely efficient in Class II, division 2 cases. The major advantage of this activation over the other designs shown is that the wire can *advance* and *intrude* the teeth while the spaces are closing and the curve of Spee is leveling (it's like getting four activations at once). Finally, Figure 5 shows the addition

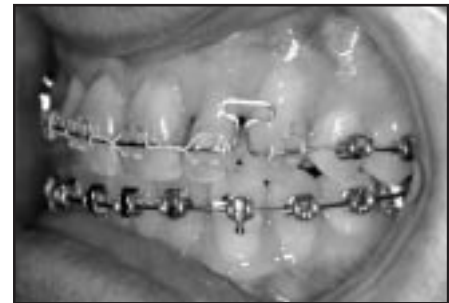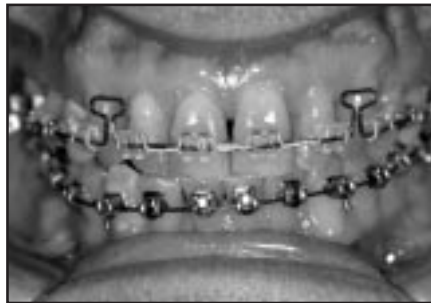continued on following page

of gabbling torque in the wire by placing an activation at the mesial vertical step of the loop. The torque is applied without losing the closing ability of the "T" Loop. With these adjustments incorporated, it can be seen that the TMA "T" Loop archwires can be used in many general and in an additional few particular clinical situations.

1. As has been mentioned, this is the wire of choice in treating Class II, division 2 malocclusions. It seems to be even more well suited for the hard-to-treat adult Class II, division 2 case due to its superior bite opening qualities coupled with the fact that torque and incisor advancement can be added.
2. The light action of this wire, when added to its flexibility, makes it again the treatment of choice when closing spaces with ceramic brackets. The ability to add torque is also of great benefit. Being able to use a wire that allows the placement of the gabbling torque allows for space closure and ideal axial inclination in this ordinarily difficult situation. Figures 6-9 show just such a case where these first two points are demonstrated.
3. Periodontally involved dentitions and patients with low pain tolerance are other situations where the TMA "T" Loop is extremely beneficial. I have used this wire in both situations with some trepidation and have not found the force levels to exceed that which can be tolerated in these cases, while still achieving the necessary clinical results.
4. Orthodontics in the 1990s has progressed to where we do not have to see our patients as frequently as in past years. The TMA "T" Loop is a great adjunct to this concept. Its light action allows a substantial activation upon placement. Its bite-opening ability and torquing qualities permit infrequent appointments, allowing for continuing this current treatment efficiency while delivering the desired clinical results.
5. I also suggest an unusual use for this wire: It can be used where no spaces need to be closed, but where any of



Figures 6-7. Pretreatment. Class II, division 2 adult deep-bite case. Note extruded canine with periodontal fragility.



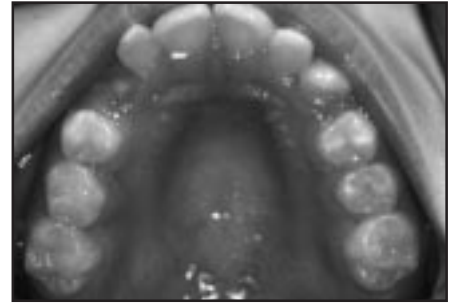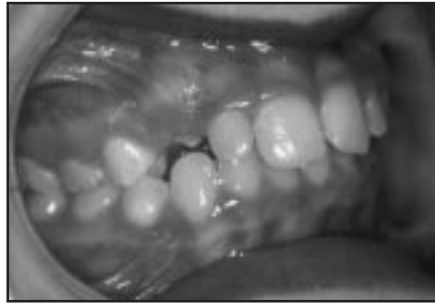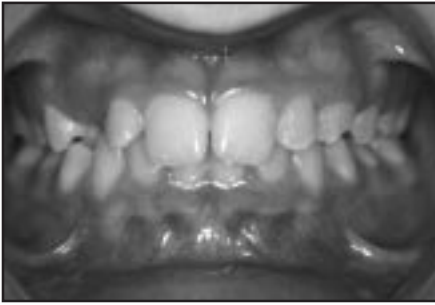
Figures 8-9. Progress photos show opened bite, improved torque and favorable periodontal response to TMA "T" Loop mechanics.

the previously mentioned situations occur. Use it in any Class II, division 2 case, not only in those with spaces. Lower reverse curve wires (particularly nitinol) are very commonly used in the lower arch to achieve bite opening and leveling. Why not accompany them with the TMA "T" Loop wire on the upper? The activations described above can be placed to augment their actions. A greater bite-opening force will be delivered. Better torque can be achieved earlier in treatment. The "T" Loops themselves can be used to hook elastics, where needed, and if any spaces occur from the additional torque delivered, they can be activated to control these spaces!

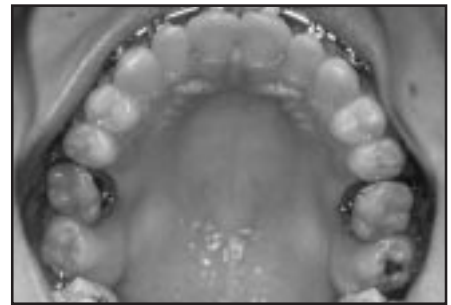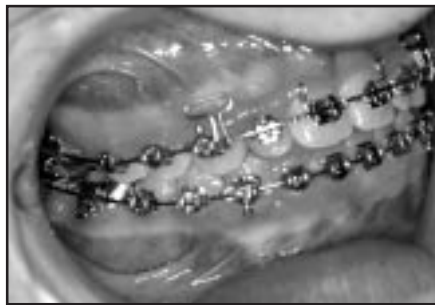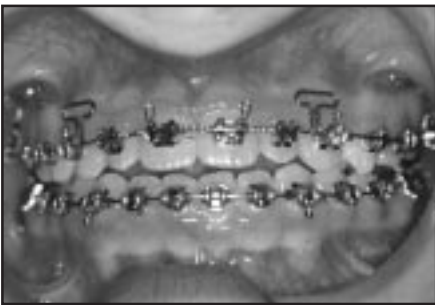Limitations to Reverse Curve TMA with "T" Loops Usage

1. Since TMA, nitinol and other space-age alloys generally exhibit more friction than stainless steel, I sometimes use stainless steel archwires when there is considerable space to close mesial to

the cuspids. Newer low-friction forms of TMA produced by ion implantation, however, exhibit excellent performance in sliding mechanics. Although not available in the TMA "T" Loop configuration, the low-friction TMA wires, both plain and in colors, are now available from Ormco. The process takes place in a vacuum and involves the extraction of oxygen and nitrogen ions and their implantation into TMA wires. These ions penetrate the wire surface by reacting with the tin in the TMA to change the surface and immediate sub-surface of the material. This layer is very hard and creates considerable compressive forces. These forces improve the fatigue resistance and ductility while reducing the coefficient of friction to roughly the same as same-dimension stainless steel. The beauty of this process is that this is not a coating that can chip or alter the dimension of the wire. The color is permanent and is available in purple, aqua, violet and honeydew bronze. When sliding

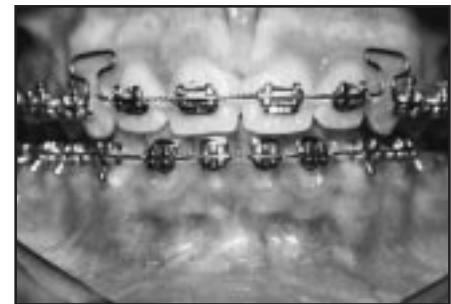
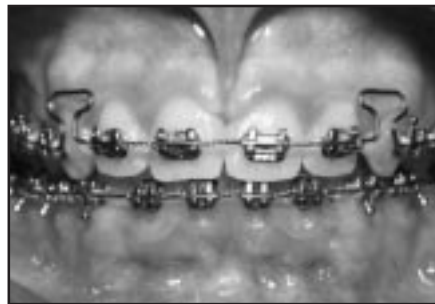
Figures 10-12. Pretreatment photos of typical orthodontic case.



Figures 13-15. Progress photos reveal effects of TMA "T" Loop archwire left in place and unsupervised for 11 months. Note bite opening (Figure 13), excessive torque (Figure 14) and intruded distal marginal ridges of upper molars resulting from reverse curve action of wire (Figure 15).

- mechanics are indicated, I recommend these low-friction forms of TMA.
2. This is not a good surgical wire nor one to be left unsupervised for extremely long periods (more than six months). The continuous activity of the wire could undo a surgical correction. Likewise, extended lengths of time may provide more correction than is desired. Figures 10-15 show a situation where a TMA "T" Loop was left in the mouth of a patient who "disappeared" from our practice for 11 months. It can be seen that the wire delivered all (and more) that was desired. Note the anterior and posterior bite opening and protrusion of the maxillary anteriors.
 3. For the above reasons, cases that already exhibit procumbent incisors and anterior or posterior open bites are not good candidates for this wire.
 4. Mutilated detentions, especially where posterior teeth are missing, do not lend themselves well to TMA "T" Loop treatment. Bite opening is compromised in this situation. It would seem that the



Figures 16-17. One month's expected bite opening with TMA "T" Loop (before [Figure 16] and after [Figure 17]).

best results from this wire can be achieved if all maxillary molars, including the second molars, are banded or bonded.

Figures 16 and 17 demonstrate the expected space closure and bite opening achieved in one month using the TMA "T" Loop archwire.

continued on page 23

Lower Arch Development Using the Frozat Appliance



by **Joe H. Mayes, D.D.S., M.S.D.**
Lubbock, Texas

I have used the Frozat (*Fixed CROZAT*) for many years for lower arch development. Several things can be accomplished with this versatile appliance. Lower anteriors can be advanced, buccal segments can be uprighted and molars can be distalized, expanded and torqued. These mechanics can be accomplished easily with simple adjustments, unilaterally or bilaterally.

There are many advantages to the use of this appliance. Since it is not removable, it works 24 hours a day. It can be adjusted simply and rapidly. Many variations can be fabricated, such as longer sweep arms on one side or no sweep arms on the opposite side. The amount of adjustment creates different tooth movements. There are two primary disadvantages to using the appliance: (1) The sweep arms can "ride up" on the occlusal of deciduous teeth and (2) Since the appliance is working all the time, untoward results may occur if a patient disappears. The problem of the sweep arms riding up on the occlusal surface is best handled by placing bonding material occlusally to the arm on the lingual of the D/4.

The basic appliance is fabricated as shown in Figure 1, using .038 round stainless steel wire. The arms extend to the middle of the lower laterals and can be extended to cross over if the lower centrals need to be advanced. This decision would be part of the original treatment plan. The appliance is based on simple physics. One side or both sides may be activated; laws of physics apply and will work both sides at the same time. If average root surface ratios are examined, it is easy to understand the how and why of adjusting the appliance to achieve the desired movements.

Note the illustration of the root surface areas of the lower teeth shown in a lateral (transverse) direction (Figure 2). It takes approximately 150 to 200 grams of force per square centimeter of root surface to create efficient tooth movement. Figure 3 shows the root surface areas of the teeth in the lower arch in a mesiodistal (horizontal) direction. Using information from the surface area ratings, it is easy to understand how the expansion of one side of the arch will distalize the molar on the opposite side (Figure 4). This is the basis of appliance adjustments. This response also applies to the upper teeth and can cause the upper molars to distalize when a

A native of Crane, Texas, Dr. Joe H. Mayes received his B.S. from Texas Tech University, followed by his D.D.S., M.S.D. and certificate in orthodontics from Baylor College of Dentistry. Dr. Mayes is engaged in the private practice of orthodontics in Lubbock, Texas, and has been actively involved in new product development.

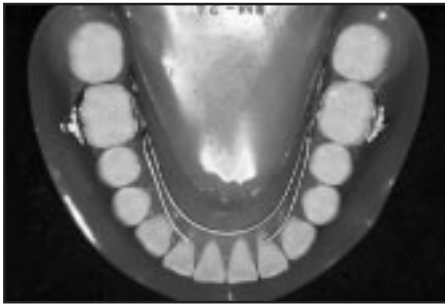


Figure 1. Basic Frozat design.

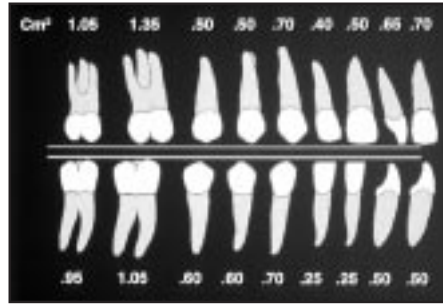


Figure 2. Root surface areas of the teeth in the transverse direction in square centimeters.

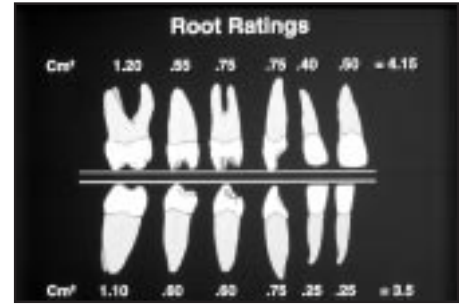


Figure 3. Root surface areas of the teeth in the mesiodistal direction in square centimeters.

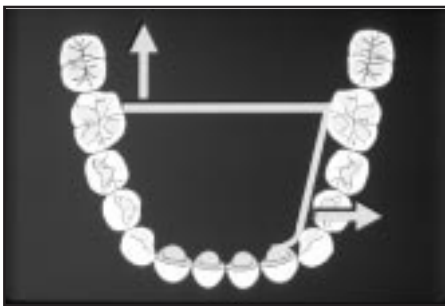


Figure 4. By pitting several teeth on the opposite side of the dental arch against the molar, the molar has no choice but to move distally.

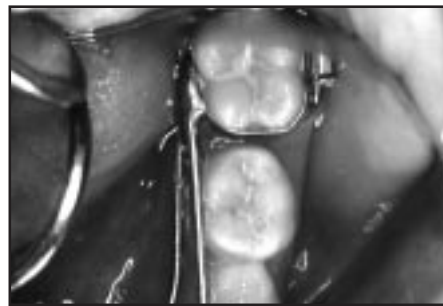


Figure 5. Observe the 1.5-2.0 mm space mesial to the lower 1st molar.

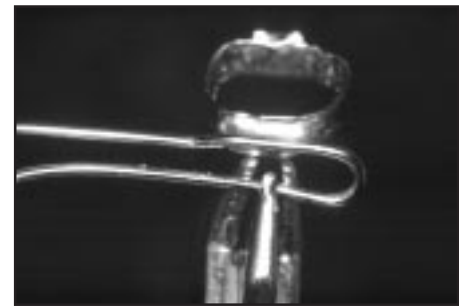

Figure 6. Three-prong plier positioned on the lower lingual bar to activate the appliance.

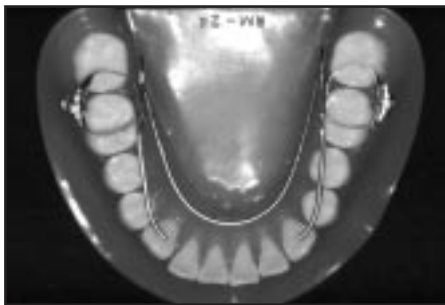


Figure 7. Sweep arms are adjusted to an approximately parallel position (clinical) to effect molar distalization.

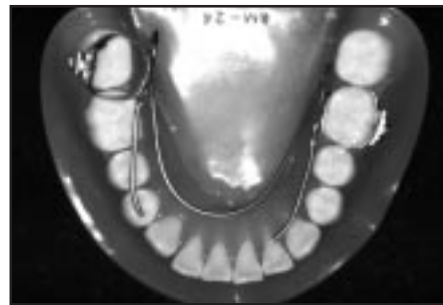


Figure 8. Band seated on one side to check activation and expansion of opposite side molar.

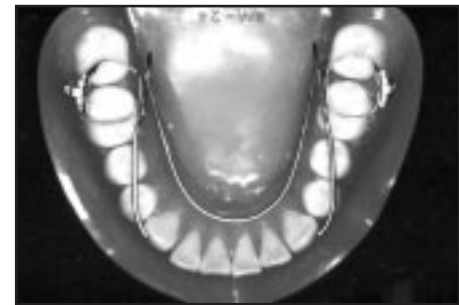


Figure 9. Frozat sweep arms activated beyond parallel (clinical) to effect molar distalization and expansion.

transpalatal bar with bilateral rotations is placed. The upper molars will not rotate to the distal but will move distally due to the force caused by rotation of the molar on the opposite side.

If distalization of the lower molars is desired, adjust the sweep arms to contact all teeth in the opposite side of the dental arch in order to engage as much root structure as possible (Figure 5). Then

before the appliance is cemented, adjust the arms with a three-prong plier on the lingual of the appliance (Figure 6). The arms are adjusted to approximately parallel each other (Figures 7-8). This will distalize the lower molar on the opposite side – the reason I don't use lip bumpers. Why does the molar move distally? Because the 1.10 square cm root surface of the molar's distal surface is competing against 2.15 square cm root surface

in the other side of the arch.

If distalization and expansion of the opposite side are desirable, adjust the arms beyond parallel (Figure 9). This will expand the arch and distalize the molars. Clinically, the arms need to be adjusted beyond parallel to have enough force to expand the larger area of root surface. Normally, I do not attempt contact with

continued on following page

Dr. Mayes

continued from previous page

all the teeth, as the arm will correct arch irregularities as the desired expansion occurs.

If only expansion is desired, the appliance is adjusted as shown in Figures 10-11. This adjustment will not distalize the molars but will expand the arch mesial to them.

Several other adjustments can be made. Molars can be expanded by moving the three-prong plier distal to the molar when activating (Figure 12). Torque may be applied to the lower molars, and the ante-

rior teeth may be advanced by activating the most anterior part of the arms. Do not try to make overly large advancements, as the appliance can easily be removed, adjusted and recemented in a few moments.

If the appliance is to be used in the mixed dentition, it is advisable (due to the shape of the linguals of the D's and E's) to bond some material on the lingual-occlusal of the D's to prevent the arms from riding up over the occlusal surface of the lower dentition.

Figures 13-20 illustrate pre- and post-

Frozat treatment of approximately four months' duration. I have found the appliance to be very useful in developing the lower arch and have used it exclusively for several years. If used in early treatment, hold the gain with a fixed lower lingual bar. If used in the permanent dentition, it facilitates bonding of the lower arch.

My goal is to create a Class I uncrowded case before placing braces on the teeth, so that the braces remain on the teeth for the shortest possible time. The Frozat is a valued ally in achieving this goal for the lower arch.

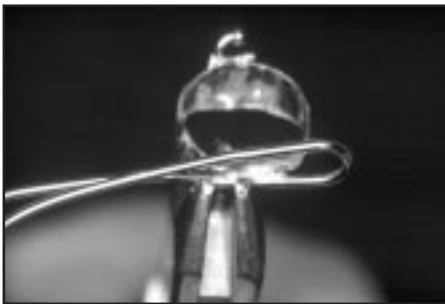

Figure 10. The three-prong plier is placed to hold appliance in place while the sweep arm is activated laterally.

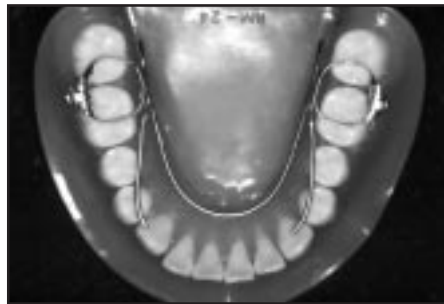


Figure 11. Frozat activated to expand only.

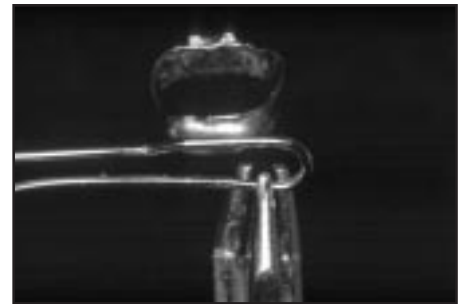

Figure 12. Three-prong plier placed to activate and expand the same side molar.

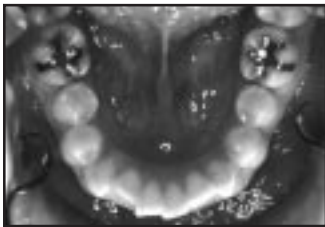


Figure 13. Patient M.T., age 16 years 4 months, before Frozat Tx.

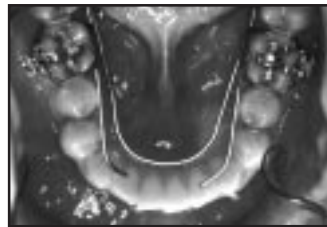


Figure 14. Patient M.T., age 16 years 8 months, posttreatment.

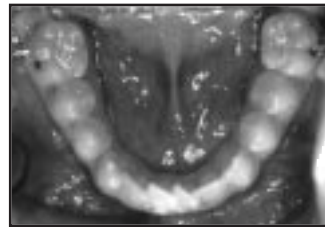

Figure 15. Patient S.C., age 12 years 5 months, before Frozat Tx.

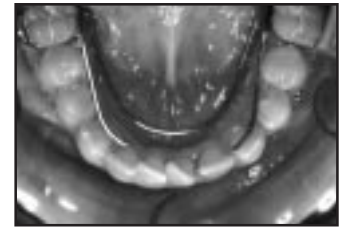

Figure 16. Patient S.C., age 12 years 9 months, posttreatment.

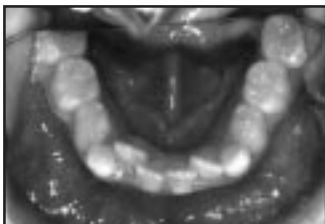

Figure 17. Patient L.C., age 9 years 2 months, before Frozat Tx.

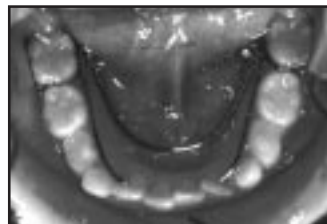


Figure 18. Patient L.C., age 9 years 6 months, posttreatment.

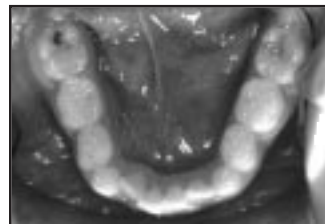

Figure 19. Patient R.J., age 10 years 4 months, before Frozat Tx.

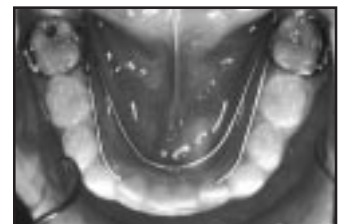

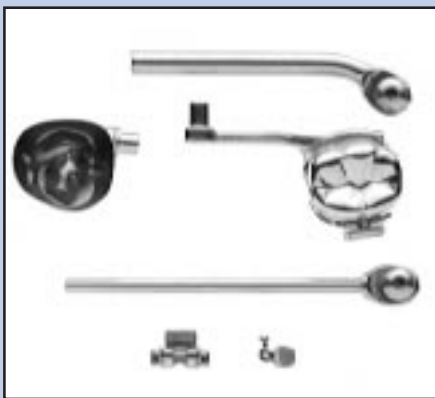Figure 20. Patient R.J., age 10 years 8 months, posttreatment.

Simplified Treatment Mechanics – The Straightaway to Practice Profitability

Through mechanics and product innovations based on his concept of Simplified Treatment Mechanics (STM), Dr. Joe Mayes has established himself as a pacesetter for greater practice efficiency. In essence, STM involves:

- First, correcting the width;
- Second (or totally or partly in conjunction with the first step), correcting the anteroposterior discrepancy;
- Third, placing braces on uncrowded Class I cases.

The watchword in Dr. Mayes' large practice could be: "Don't waste time – doctor's, staff's, patient's or parent's." Scheduling is orchestrated so that more is accomplished with each patient visit and total visits per patient and doctor chairtime are minimized. His no-nonsense practicality stems from a background of two years' studies in mechanical engineering and a two-year stint in the U.S. Army as a dental laboratory technician prior to commencing pre dental, dental and orthodontic training. Two highly popular product developments stemming from Dr. Mayes' straightforward approach to orthodontics, the single-appointment Cantilever Bite Jumper (CBJ) and Bite Turbos, reflect his focus on efficiency and effectiveness:



The Single-Appointment CBJ

The CBJ can be routinely delivered in 45-60 minutes. Patients and parents don't have to make repeated trips to the office. There is no problem with lost separators aborting the delivery of an appliance as scheduled. Detailed information on CBJ


fabrication and application is provided in Dr. Mayes' article, "The Single-Appointment Preattached Cantilever Bite Jumper," published in *Clinical Impressions*, Volume 5, No. 2, 1996.

The 20-patient CBJ Kit provides the essential components for the single-appointment Cantilever Bite Jumper. A complete size range of laser-marked first molar crowns (seven per quadrant) is provided – 80 crowns distributed according to popular usage. Upper crowns are supplied complete with nickel-brazed axles, while all lower crowns come with nickel-brazed cantilever arms that are specifically designed for maximum strength and optimum patient comfort. Each cantilever arm has an axle with an .022 tube occlusal to it for use with bonded cases. All necessary components for 20 cases are also supplied, including rods, sleeves, Hex-Head screws and a Hex-Head Allen wrench. Hex-Head screws are used for all appliances to increase accessibility and improve performance over conventional slot-head screws. The CBJ saves the expense of additional chair time, doctor time and staff time, and costs significantly less than using a commercial lab.

The CBJ Fit-Kit provides one loose crown in each of the 28 sizes for trial fitting in order to avoid having to trial fit (and possibly deform) the more expensive crowns with attachments. Prewelded Precision™ Lingual Hinge Caps are an option for the lower arch (and upper as well when TPAs or other auxiliaries are planned) to eliminate all soldering and lab work except for pouring models. If Hinge Caps are used, Snug Fit .032 x .032 wire (available in straight lengths or preformed lingual arches) is recommended for achieving an ideal fit with lingual or transpalatal arches. Peerless® M/P .022 buccal tubes are also available nickel-brazed to upper molar crowns for use in bonded cases.

Crowns with attachments and Allen wrenches can be reordered separately

(no minimum). Loose crowns (any mix of sizes) and other components can be reordered in packs of ten. For order information, see page D of the Center Section.



Bite Turbos

As described in Dr. Mayes' article, "Bite Turbos...New Levels of Bite-Opening Acceleration," published in *Clinical Impressions*, Volume 6, No. 1, 1997, Ormco anterior Bite Turbos immediately open the bite. One to four can be placed on the lingual of upper incisors, allowing placement of lower anterior brackets without their being knocked loose or causing displacement of the mandible.

Ormco Bite Turbos are modifications of lingual incisor brackets. Their bite planes are horizontal to the occlusal plane to avoid creating a distal force on the mandible. The flat surface and deeper anteroposterior dimension of the bite plane generate faster bite opening while preventing dislodgment of lower anterior brackets. Since there are no slots or tie wings, Bite Turbos are easier to clean than conventional lingual brackets. Placement and removal are also simpler and quicker than with composites, splints or bite planes. No lab fee. No worries about fit or adaptation. Bite Turbos – the simple, efficient, economical answer to deep bite problems. Order information is provided on page D of the Center Section.

very helpful, of course, to keep it light, and most of us have developed our own special ways of doing so. After some general reference to the photos, I'll proceed with my exam. We prefer the Orthotrac Communications Module whereby I can articulate my findings with the assistant entering the information directly into the computer. It is both thorough, in that it prevents oversights by walking you through the exam, and efficient, in that it allows for a written summary to be given to the parent that day to take home. It also generates a written report for the referring doctor. As always, word choice is important, and I generally ask for the patient's understanding while I call out some observations about Jennifer's teeth and facial features. This allows me to provide a written summary to them at the conclusion of our meeting. I convey that I will then be able to fully explain my findings. Most patients are more than passively impressed with this high-tech, high-touch technique.

If it appears that the patient is a candidate for treatment and the parent is agreeable, I suggest that we gather the remaining information needed to make a definitive diagnosis. Then I present the findings in a one-step approach (which we generally prefer), but if a spouse is going to be important in a decision or I am unsure regarding the probable success of the one-step approach in a particular instance, I will present the findings at a later consultation. We do about 60 to 70 percent one-step consultations, placing separators at this first visit.

If we are going the one-step route, we proceed in the conventional way, except that in our practice, we turn the patient over to our administrative coordinator after my input. She then can establish rapport, make the appropriate appointments and do the usual procedures associated with integration into the practice, including arriving at an appropriate financial arrangement and explaining the payment policy. Importantly, in establishing rapport, we use the consultation

room station of our imaging system. Using the images, the administrative coordinator compliments the patient (e.g., "Oh, Jennifer is such an attractive young lady. I can't wait to see her with her new smile."). She also uses the opportunity to compliment the doctor. She might say, "You know, I've been with Dr. Weinberger for many years, and what impresses me among other things is that even though he has so many patients, he cares about each and every one of them." The goal is to take this opportunity to enhance the credibility of the doctor and the entire practice, as well as to ensure that the patient and parent are having a unique office experience beyond their expectations.

We have found it important to follow up one-step consultations the following day to confirm that there are no additional questions the patient or parent might have thought of and to reassure them about the upcoming visit and treatment in general. This also serves to reinforce the depth of individual attention and concern of the practice.

Keeping Track

An easy and readily available means of monitoring our effectiveness in delivery is a common video camera, something virtually all of us have. This can be easily set up in the records area to check the effectiveness of our verbal, vocal and visual impressions. We can also evaluate the posture, eye movements and other visual features of our presentations, which can be of enormous value in improving our effectiveness. Simple cassette recorders are also a valuable means of hearing what we say and how we say it.

Conclusion

The goal of the ideal practice, according to Frank Edwards, a well-known management consultant, is to make a missionary of every patient. In order to accomplish this, we must exceed each patient's legitimate expectations in everything we do. There are no unimportant details. Success is everything done right; failure may be one thing done wrong. At no time is

this more important than at the first encounter. That is why you need a comprehensive plan that takes advantage of new technologies and expert communication skills in reaching your chosen practice objectives. Take the time to listen to your patients and refine your skills to communicate with them more effectively. Involve the entire team.

Not long ago, I was on a transatlantic flight and had been given a business-class upgrade. This particular carrier "did it right." Seemingly, every reasonable comfort was provided, every possible amenity was considered. And it showed. Whatever could be done on an aircraft was done in the typical European tradition. I certainly felt I got more than my money's worth for my discounted coach fare. More recently, I flew the same carrier, paying a full business-class fare. I was enlightened as to how much more critical I became after paying in excess of ten times more for the same experience. The service was essentially the same, but my expectations were higher, considering my outlay. It was that much harder for the carrier to please me. My point is that our patients likely think in the same terms. We can't, as a motto in our practice goes, give a coach experience for a business-class fare. We simply have to come up with the solutions that will encourage our patients to seek our services and pay for them willingly.

In our moments of challenge, we need a vision of how to go above and beyond. How to make the most out of every opportunity. It is that vision that provides insight. The teamwork we build serves as the fountain from which all our rewards will ultimately flow. As Orison Set Marden expressed, "It is just the little difference between the good and the best that makes the difference between the artist and the artisan. It is just the little touches after the average man would quit that make the master's fame."

Bibliography:
Decker, B., *You've Got to Be Believed to Be Heard*, St. Martin's Press, 1992, New York, NY.
Louis Allen Associates, *An Introduction to the New Millennium*, Mountain View, CA.

Dr. Bagden

continued from page 17

Figures 18-29 display a typical case treated with this wire. Note the initial deep bite. All spaces are consolidated prior to wire insertion. Single-tie or figure-8 ligation of the four maxillary incisors maintains their proximity during the cuspid retraction process. Once the wire is inserted, the bite simultaneously opens while the spaces close. The case is finished with a light TMA wire having a very slight step-up to ensure that final bite opening is accomplished.

Summary

The principles of the Reverse Curve TMA with "T" Loops design and metallurgy have been explained and their application to the treatment of different orthodontic situations has been presented. The objective has been to demonstrate the actions of this wire and present clinical situations which may be useful to treatment. While

this wire may not be the endpoint on the road of orthodontic treatment, it appears that progressive treatments at this time would wisely employ this modality.

Bibliography

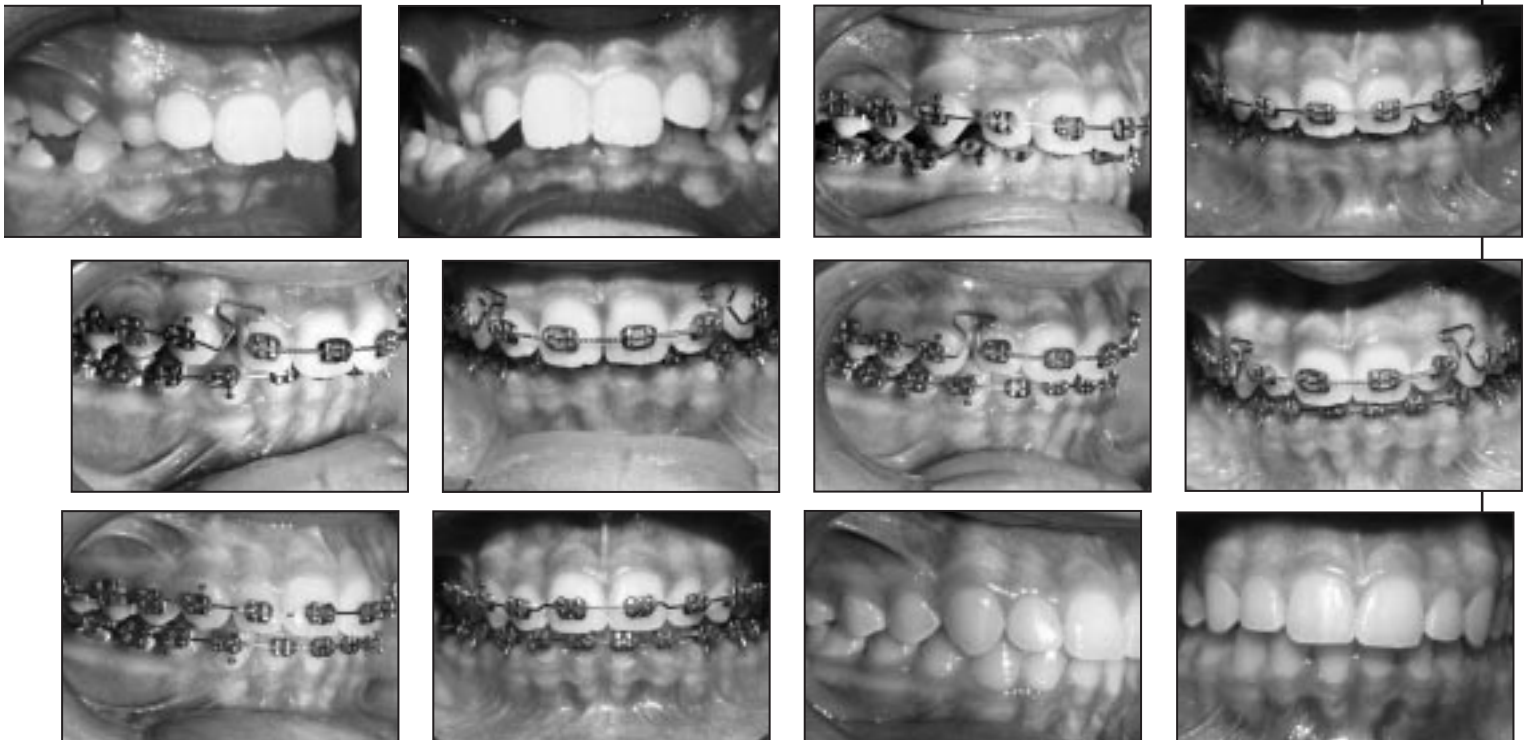
- Shia, G., Broussard, G. and Broussard, C.: Broussard Two-Force Technique. Rocky Mountain Orthodontics, pp. 46-59.
Broussard, G., Broussard, C. and Shia, G.: Treatment of Class Malocclusion Using the Broussard Two-Force Technique. *Journal of Clinical Orthodontics*, February 1977, pp. 126-142.
Burstone, C. and Farzin-Nia, F.: Production of Low-Friction and Colored TMA by Ion Implantation. *Journal of Clinical Orthodontics*, July 1995, pp. 1-12.
Ormco Corporation Material Safety Data Sheet.
Swartz, M.: Increasing Utility Arch Efficiency with Beta Titanium Wire. *Clinical Impressions*, Vol. 1, No. 4, 1992, pp. 2-5.
Hilgers, J.: *The Essence of Practical Orthodontics*, Ormco, Section VII.

Reverse Curve TMA[®] with "T" Loops

The memory and loop configuration of this versatile wire allow for effective multipurpose use of this loop system in a continuous archwire. The archwires are available in three wire sizes in 5-packs of six lengths: .016 x .022, .017 x .025 and .019 x .025. Each length is color-coded at the midline. Order information is provided on page D of the Center Section.



Case Presentation



Figures 18-29. Typical deep-bite Tx with TMA "T" Loop

Lecture/Course Schedule at a Glance – Through May 1998

Date	Lecturer	Location	Sponsor, Contact and Subject
12/2-5	Wick Alexander	Manila, Philippines	AVM Ortho Trading; Ms. San Agustin 632 843 6208; Alexander Discipline Advanced
12/5-7	Michael Marcotte	Munich, Germany	Ormco (Europe) AG; Nicole Ommert 41 1 306 51 11; Ortho Case Analysis & Tx Planning
12/6-7	Wick Alexander	Jakarta, Indonesia	P.T. Medikapurna Estetika; Ms. Siregar 62 21 751 0484; Alexander Discipline Advanced
12/9-13	Wick Alexander	Bangkok, Thailand	Thailand Intl. Congress; "Tx of Transverse Discrepancies in Growing & Nongrowing Patients"
12/9-13	Wick Alexander	Bangkok, Thailand	Thailand International Congress; "Skeletal Discrepancy Solutions"
12/10-12	Kyoto Takemoto	Bangkok, Thailand	Thailand International Congress; Lingual Orthodontics
12/10-13	Jim Hilgers	Bangkok, Thailand	Thailand Intl. Congress; Lecture—"Mgmt. of Skeletal Discrepancies & Interdisciplinary Tx"
12/14-16	Didier Fillion	Paris, France	Dr. Fillion (Fax) 33 1 47551833; In-Office Lingual Ortho, Typodonts, Lab & Clinic*
1/9	Wick Alexander	Los Angeles, CA	USC; Dr. Sinclair (213) 740-4242; Practice Management
1/12	Jim Hilgers	Ann Arbor, MI	U of Michigan; Dr. McNamara (313) 763-1565; "The Way Orthodontics Really Ought To Be"
1/16-17	Terry Dischinger	Orlando, FL	Specialty Appliances (800) 522-4636; Edgewise Herbst Appliance
1/16-17	Courtney Gorman	Indianapolis, IN	Indiana U.; Ms. Manion (317) 274-7782; Lingual Orthodontics Comprehensive*
1/18-20	Wick Alexander	Paris, France	AOSM; Josiane 33 1 48591617; Alexander Discipline Comprehensive*
1/19-21	Didier Fillion	Paris, France	Dr. Fillion (Fax) 33 1 47551833; In-Office Lingual Ortho, Typodonts, Lab & Clinic*
1/22-23	Wick Alexander	Paris, France	AOSM; Josiane 33 1 48591617; Alexander Discipline Advanced
1/24	Wick Alexander	Paris, France	AOSM; Josiane 33 1 48591617; ADI Study Group Meeting
2/6-7	Wick Alexander	Durham, NC	North Car. Ortho Society; Dr. Hamilton (704) 324-4535; Tx & Retention for Long-Term Stability
2/16	Jim Hilgers	Phoenix, AZ	Ormco; Dr. Henry (602) 991-9811; "Hyper-Efficient Orthodontics"
2/19-21	Duane Grummons	Marina del Rey, CA	Dr. Grummons; Kaci (310) 822-8711; "Orthodontics & TMD Co-Management"
3/6	Joe Mayes/Paula Allen	Denver, CO	Ormco; Katie (800) 854-1741, Ext. 7573; "Fitting and Removing the CBJ"*
3/19-21	Didier Fillion	Kyoto, Japan	JLOA; Dr. Hamanaka 81 742 46 9498; Lingual Orthodontic Typodont Course*
3/20	B. Brunner/J. Piankoff	Houston, TX	Ormco; Katie (800) 854-1741, Ext. 7573; "Round Peg...Round Hole"
3/23-24	Luis Batres	Panama City, Panama	Dr. Batres (507) 264-3920; Lingual Orthodontics*
3/25-26	Rand Bennett	Tokyo, Japan	Ormco Japan; R. Kishi 81 3 3432 0065; Effective Tx to Achieve Quality Results
4/17-18	Jim Hilgers	Pinehurst, NC	Ormco; Todd Blanton (800) 854-1741, Ext. 400; "Hyper-Efficient Orthodontics"
4/20	Wick Alexander	Oakbrook Terrace, IL	Illinois Ortho Society; Dr. Hayward (847) 382-5589; The Verification of the Alexander Discipline
4/20-22	Didier Fillion	Chicago, IL	Fillion Lingual Ortho Seminars (800) 474-3633; Lingual Orthodontics
4/22-25	Jim Hilgers	Mission Viejo, CA	Dr. Hilgers; Kim (714) 830-4101; "The Essence of Practical Orthodontics"
4/23-25	Didier Fillion	Beverly Hills, CA	Fillion Lingual Ortho Seminars (800) 474-3633; Lingual Orthodontics
4/24	Barbara Brunner	Las Vegas, NV	Ormco; Katie (800) 854-1741, Ext. 7573; "Just Say It!"
4/24	Joe Mayes/Paula Allen	Atlanta, GA	Ormco; Katie (800) 854-1741, Ext. 7573; "Fitting and Removing the CBJ"*
5/1	B. Brunner/J. Piankoff	Detroit, MI	Ormco; Katie (800) 854-1741, Ext. 7573; "Round Peg...Round Hole"
5/7-9	Mario Paz	Beverly Hills, CA	Dr. Paz; Shelly (310) 278-1681; Hands-On Lingual Ortho with Typodonts & Patients*
5/15	Jim Hilgers	Dallas, TX	AAO Annual Session; Lecture – "Hyper-Efficient Orthodontics"
5/16	Joe Mayes	Dallas, TX	AAO Annual Session; Lecture – "Simplified Delivery of CBJ"
5/17	Didier Fillion	Dallas, TX	AAO Annual Session; Lecture – "How To Achieve Excellence with Lingual Orthodontics"
5/18	Jim Hilgers	Dallas, TX	AAO Annual Session; Lecture – "Class II Trans-Arch Mechanics"
5/19	Jim Hilgers	Dallas, TX	AAO Annual Session; Lecture – "Tandem Mechanics"
5/21-22	ADI	Arlington, TX	ADI; Brenda (817) 275-3233; ADI Symposium
5/30-6/1	Kyoto Takemoto	Tokyo, Japan	Dr. Takemoto; R. Kishi 81 3 3432 0065; In-House Lingual Typodont Course*

*Typodonts and/or Participation

For additional information on any course, please call the contact number shown or (international doctors) Ormco distributor.



1717 West Collins Avenue
Orange, CA 92867
(714) 516-7400
www.ormco.com