

**K.P.**

**Age:** 12 Years – 5 Months

**Diagnosis:** Class II, Division 1 Nonextraction – Youth  
(normal response to Phase I Herbst treatment)

## **Background:**

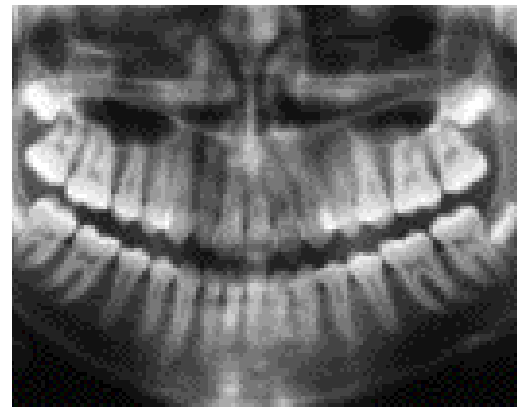
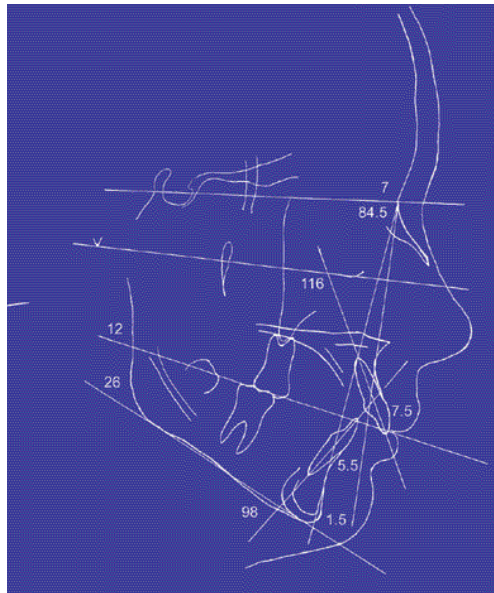
This case was selected to demonstrate the average response to a standard type of Herbst treatment. In the initial profile photograph it is very apparent that the mandible is growing slower than the maxilla. In these types of Class II cases, I have never been comfortable trying to move the maxilla or dentition back to meet a deficient mandible. This traditional headgear approach left a significant number of patients with a prominent nose, lack of upper lip support, and a very weak chin. It has always made more sense to treatment plan these cases trying to create an environment for mandibular change rather than retraction of the maxilla or maxillary anterior teeth. Please observe the beautiful impact Herbst treatment has had on this patient's facial balance and dentition. As the full bonding phase of treatment is started, we are now treating a simple Class I with increased maxillary arch width, eliminating the need for high-force palatal expansion. It is interesting to note that on this patient the upper bicuspid width change was less than is normally observed with Herbst treatment. The tongue did not completely reposition itself until after full-bonded treatment was started. Note on the final models that the first bicuspid moved laterally 10.5 mm with minimal tipping. The combination of these technologies certainly simplified the treatment plan, minimizing the need of patient cooperation, with results very rewarding to the patient and clinician.

**Facial Evaluation:**

1. Retrusive mandible.
2. Narrow mid-face.
3. Moderate overeruption of upper anterior teeth.
4. Good chin button.
5. Excessive tissue under chin (poor throat angle).
6. Disproportionate lower facial height.

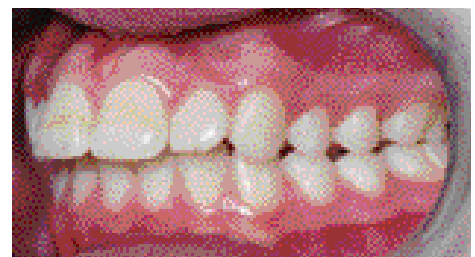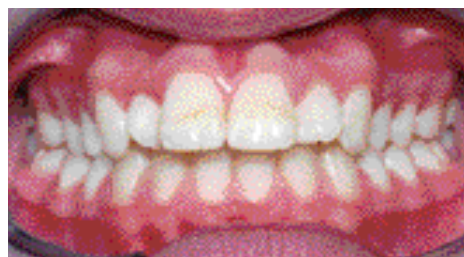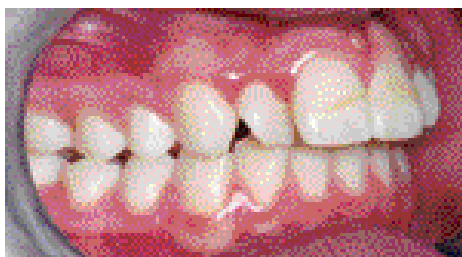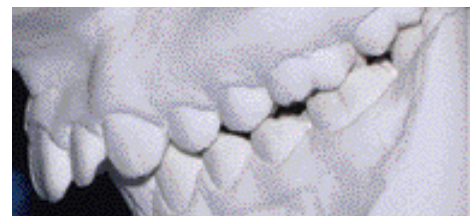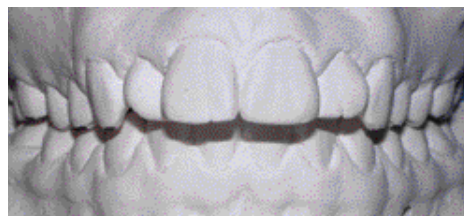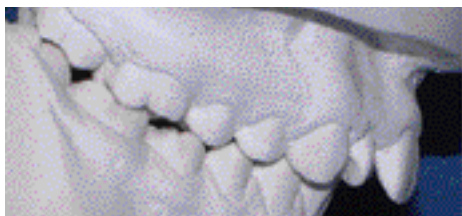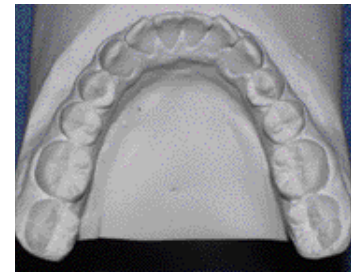


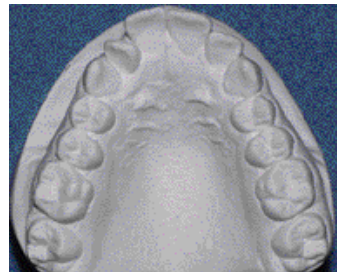**Pretreatment Radiographic Survey:**



**Dentition Evaluation:**

1. Narrowing of anterior maxillary arch, typical of Class II patients.
2. Flaring of upper incisors.
3. Moderate overeruption of lower incisors.
4. Third molars present.
5. Lingually inclined upper and lower cuspids.



### Treatment Objectives:

Goal:

Achieve outstanding profile with facial balance and symmetry of nose, lips and chin. Create upper and lower posterior arch width to support mid-face with low-force mechanics.

1. Establish upper and lower incisor position to give natural lip-to-tooth relationship.
2. May positively impact airway.

### Phase I – Herbst Treatment

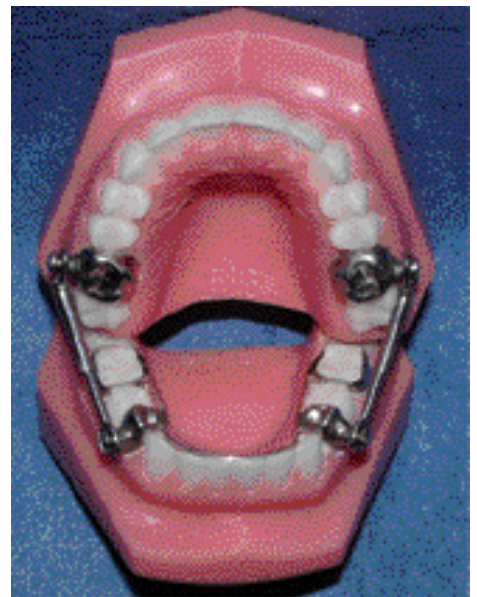
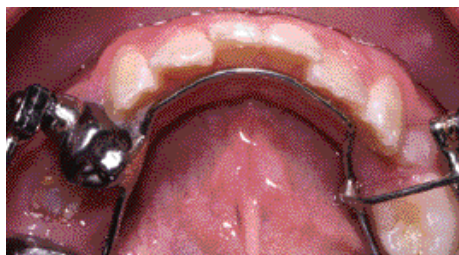
#### Treatment Sequence:

Special torques in appliance construction.

- High-torque maxillary centrals  $+17^\circ$  and laterals  $+12^\circ$ . When using a Herbst appliance, there is a tendency to upright anterior teeth. In this case we chose  $+17^\circ$  on the centrals and  $+12^\circ$  on the laterals to keep the roots of the anterior teeth from uprighting too much.

#### Start

1. Placed Flip-Lock Herbst and bonded upper central and lateral incisors.
2. Placed sectional .014 NiTi SE archwire (see Sectional archwire) extending from maxillary right cuspid to maxillary left lateral incisor with the ends of the wire heat treated and bent for comfort. Leave enough room for the anterior teeth to align.
3. Activated Herbst 4.5 mm initially.



#### Appt. 1

##### 2 months – 3 weeks:

- Placed maxillary and mandibular .017 x .025 TMA with moderate intrusive bends anterior to molar tubes. This wire is inserted in tubes soldered to the first molar Herbst crowns.

#### Appt. 2

##### 6 months:

- Placed maxillary and mandibular .019 x .025 TMA with moderate intrusive bends to intrude anterior teeth. This wire is inserted in the tubes of the first molar Herbst crown.
- Added 2 mm shims.

#### Appt. 3

##### 8 months – 2 weeks:

- Adjusted maxillary archwire.
- Added 1 mm shim.

#### Appt. 4

##### 10 months – 3 weeks:

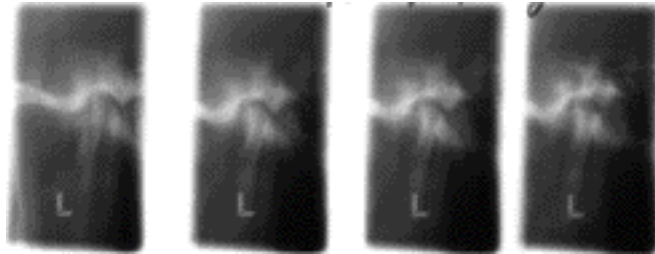
- Checked Herbst.

Appt. 5

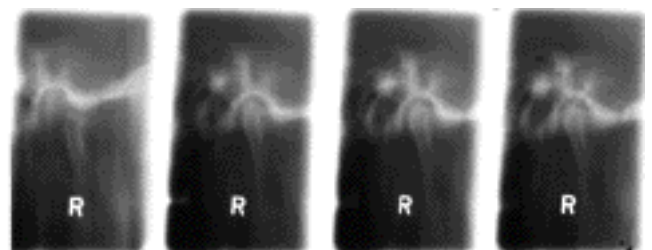
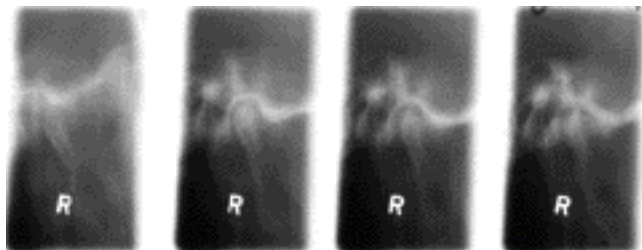
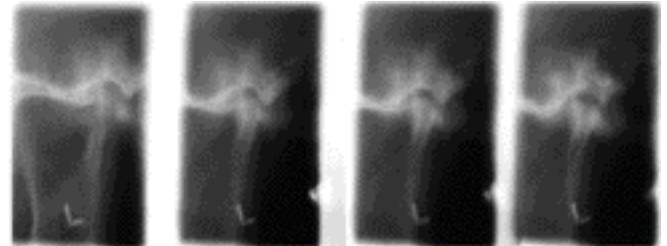
13 months – 2 weeks:

- Took tomograms and evaluated.
- Scheduled Herbst removal.

Initial



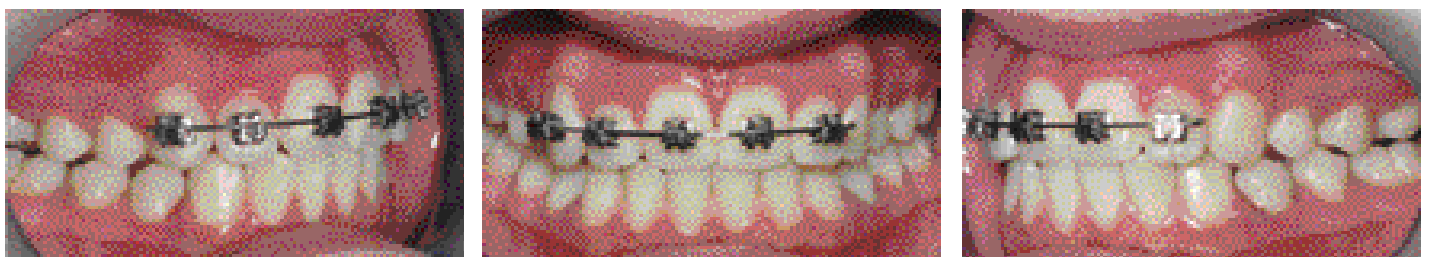
Post-Herbst



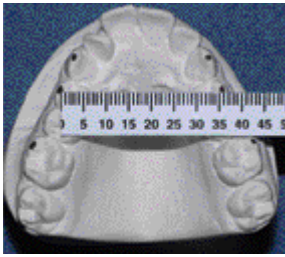
Appt. 6

16 months:

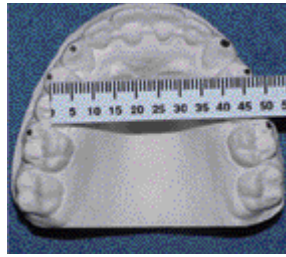
- Removed Herbst.
- Took progress records.



## Phase II – Post-Herbst Treatment

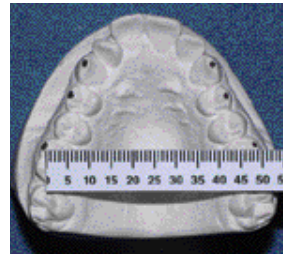

35.5 mm

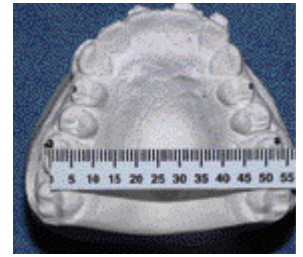


46.0 mm

10.5 mm bicuspid width change – Plus 5 mm after Herbst

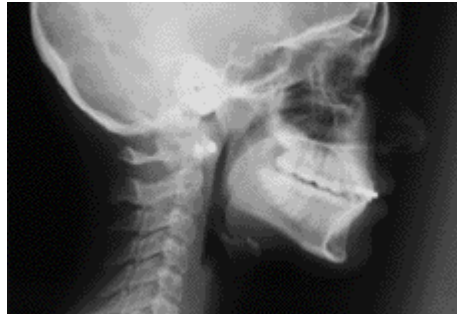

Initial 48.5 mm



Post-Herbst 53.0 mm

4.5 mm change



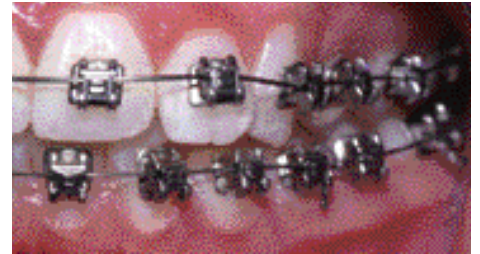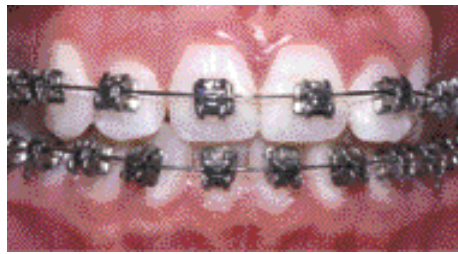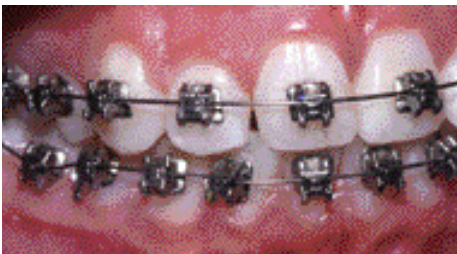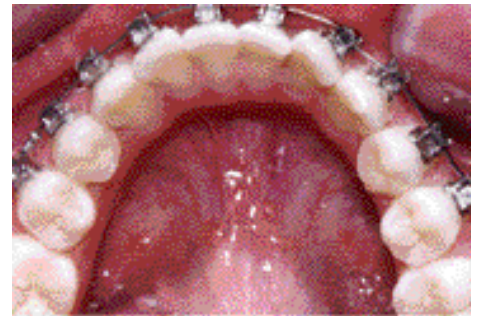Post Herbst

### Treatment Sequence:

- Selected special torques.
- Upper and lower cuspids +7°. The cuspids were slightly toed in. The +7° on the cuspids is to help upright the cuspids.

### Start:

1. Bonded maxillary and mandibular 7 to 7.
2. Placed continuous maxillary and mandibular .014 NiTi SE with crimpable stops (see Initial phase/Crimpable stops).



### Appt. 1

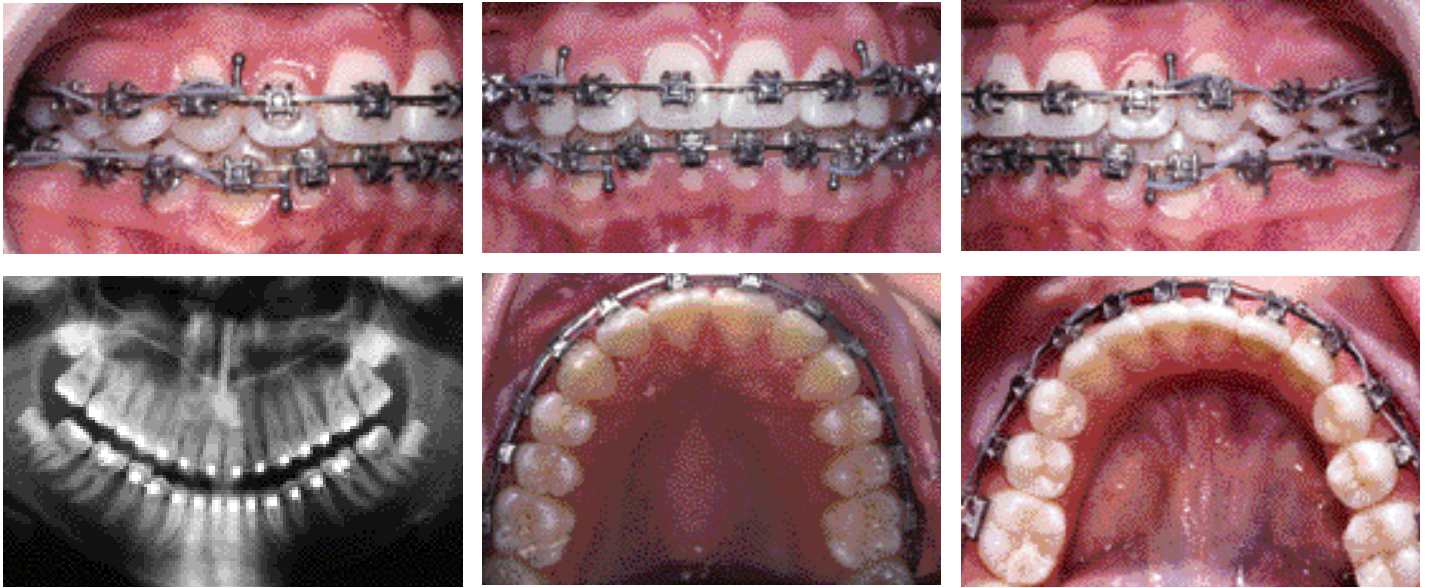
#### 2 months – 2 weeks:

- Placed upper .016 x .025 NiTi SE (see Working phase).
- Placed lower .014 x .025 NiTi SE to stay in optimal force zone (see Biozone).

Appt. 2

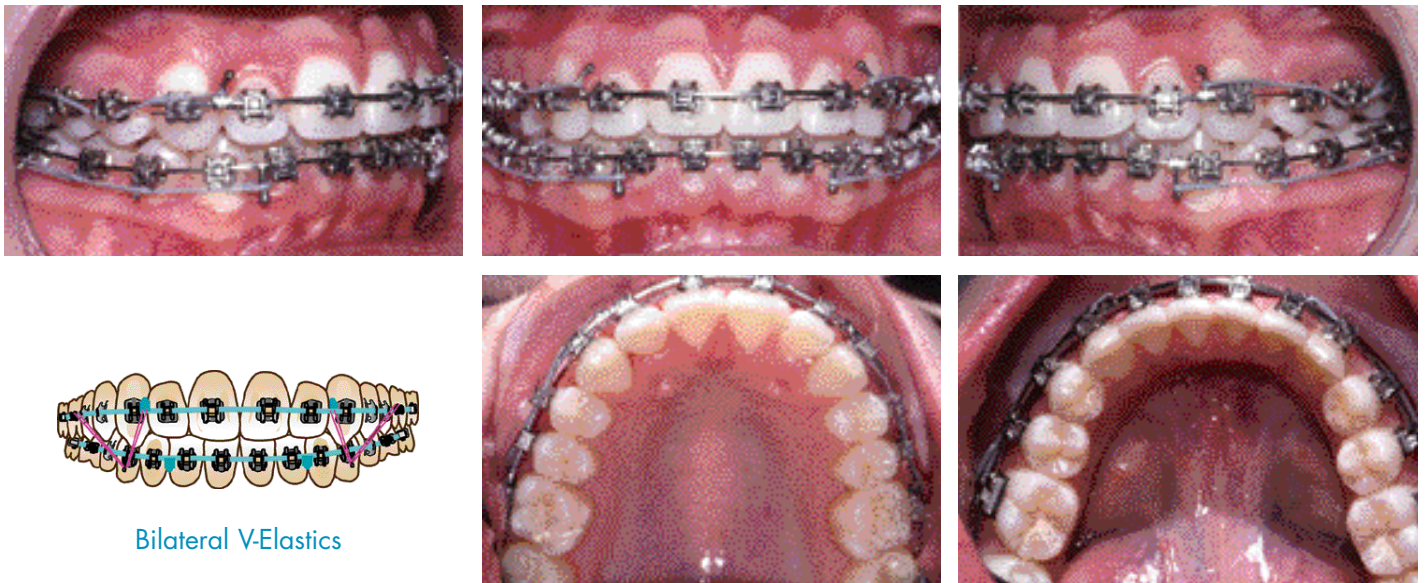
4 months – 3 weeks:

- Took Panorex to evaluate root angulations and bracket positions.



Appt. 3

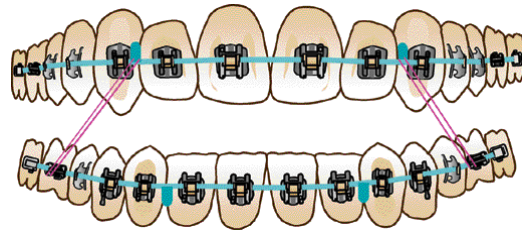
7 months – 2 weeks:



Bilateral V-Elastics

- Placed maxillary .019 x .025 preposted SS with tiebacks (see Final phase).
- Mandibular .016 x .025 preposted SS with tiebacks. This keeps play in the bracket tube to help eliminate binding. Helps to close the posterior occlusion when trying to close the bite vertically.
- Started bilateral V-elastics (see V-elastics).

Appt. 4  
9 months – 3 weeks:



Class II Elastics

- Adjusted upper and lower archwires.
- Continued full-time V-elastics.
- Added Class II elastics night only (see *Class II elastics*).

Appt. 5  
12 months:

- Adjusted maxillary and mandibular archwires.
- Posterior occlusion hard to close due to tongue repositioning (see *Tongue influence*).

Appt. 6  
13 months – 2 weeks:

- Checked occlusion.
- Continued elastics.

Appt. 7  
15 months – 1 week:

- Adjusted maxillary and mandibular archwires.
- Continued elastics.

*Finals*


*17 months:* Debonded upper and lower




Pretreatment



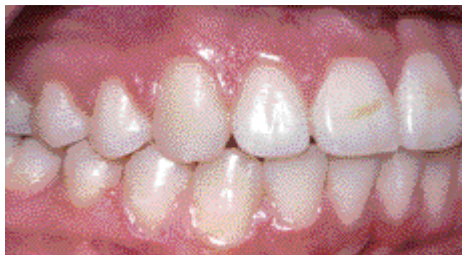Posttreatment



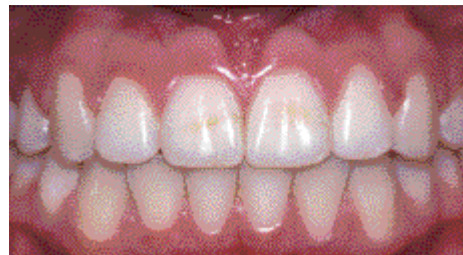Pretreatment



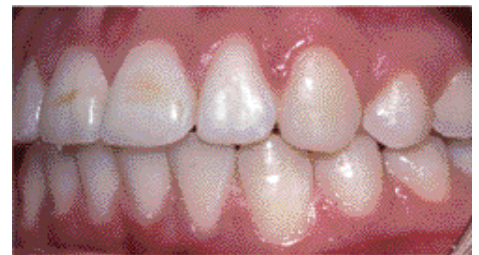Posttreatment



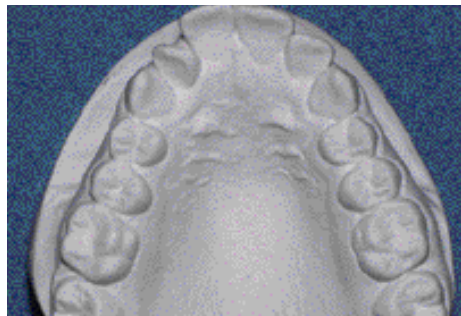
Final



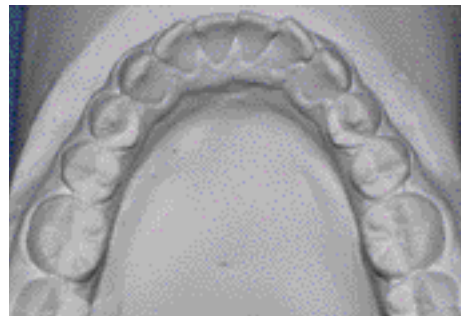
Final



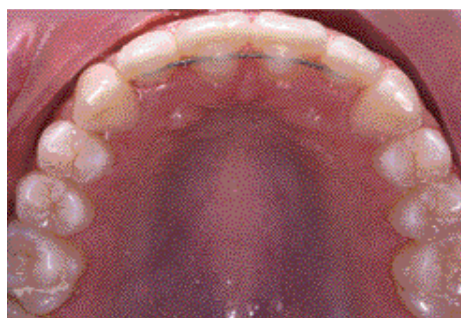Final



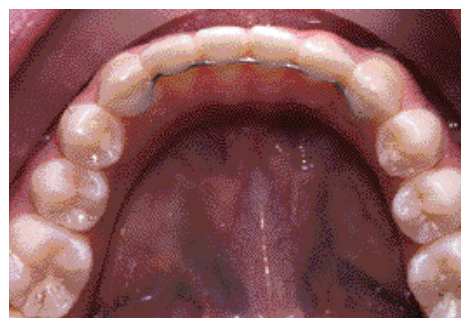Pretreatment



Pretreatment

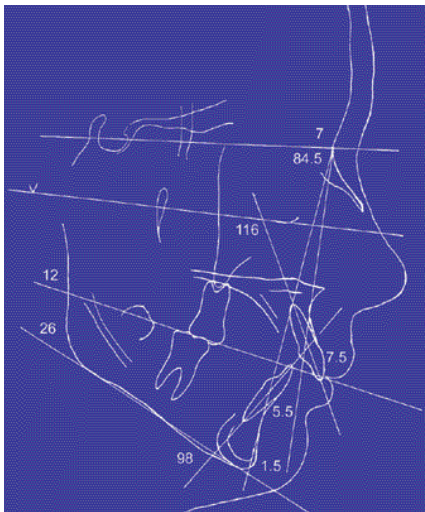


Posttreatment

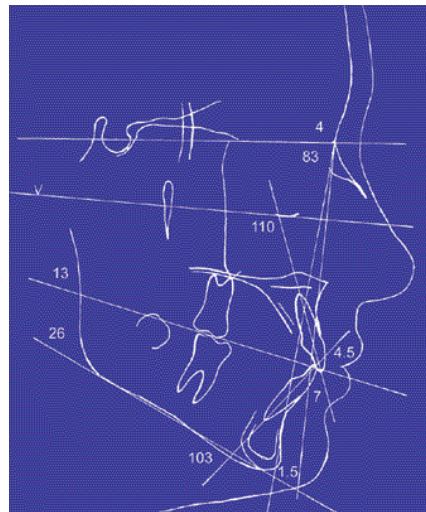


Posttreatment

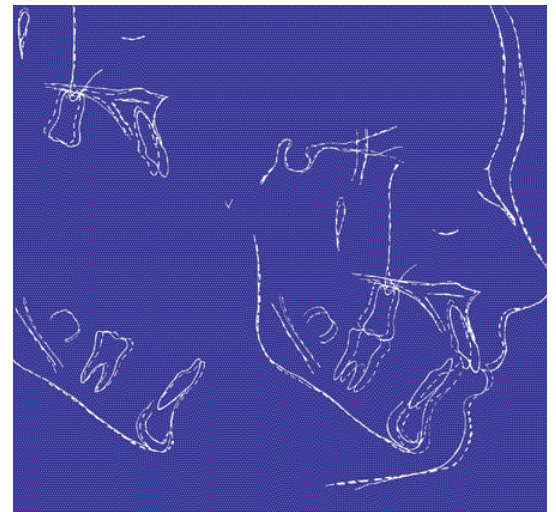



Initial



Final



Composite

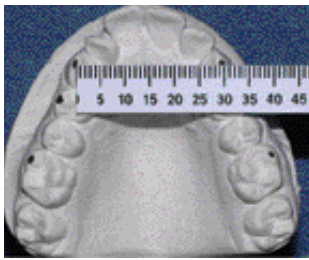*Occlusal Cast Transverse Measurement Comparisons*

Pretreatment

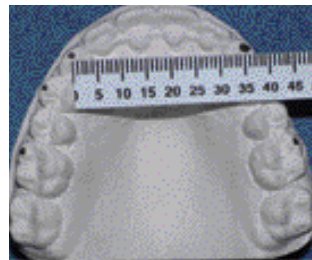
Posttreatment

Pretreatment

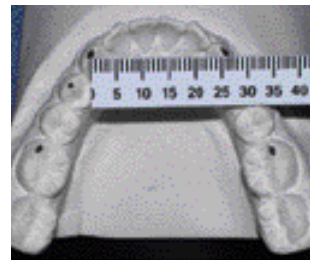
Posttreatment



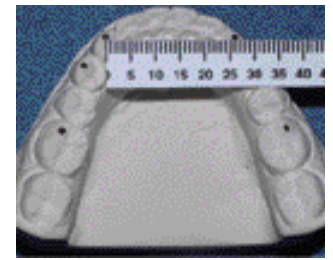29.5 mm



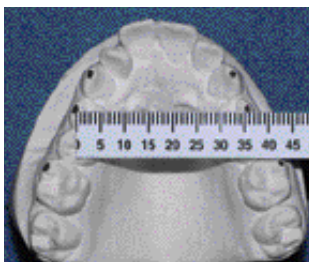
35.0 mm  
5.5 mm change



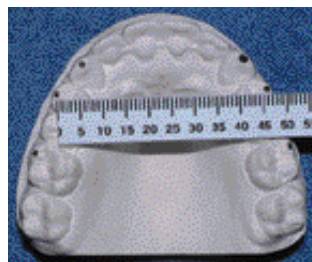
25.5 mm



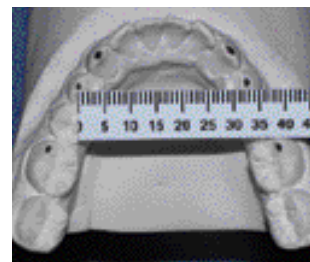
26.0 mm  
.5 mm change




35.5 mm



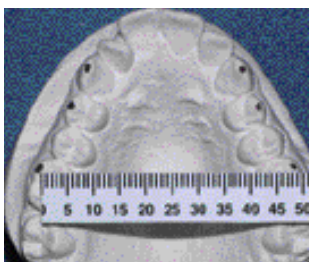45.5 mm  
10 mm change



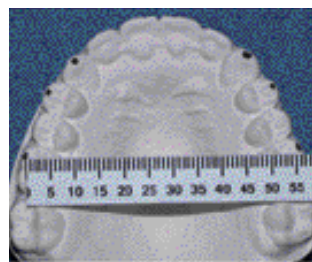
33.0 mm



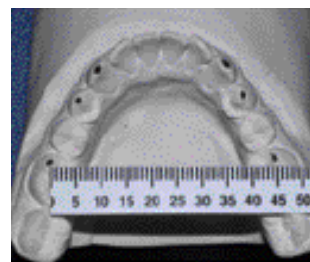
35.0 mm  
2 mm change



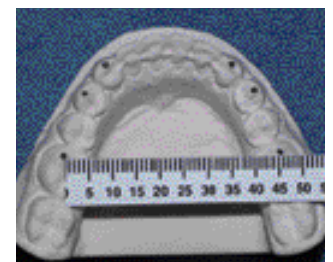48.5 mm



55.5 mm  
7 mm change



44.5 mm

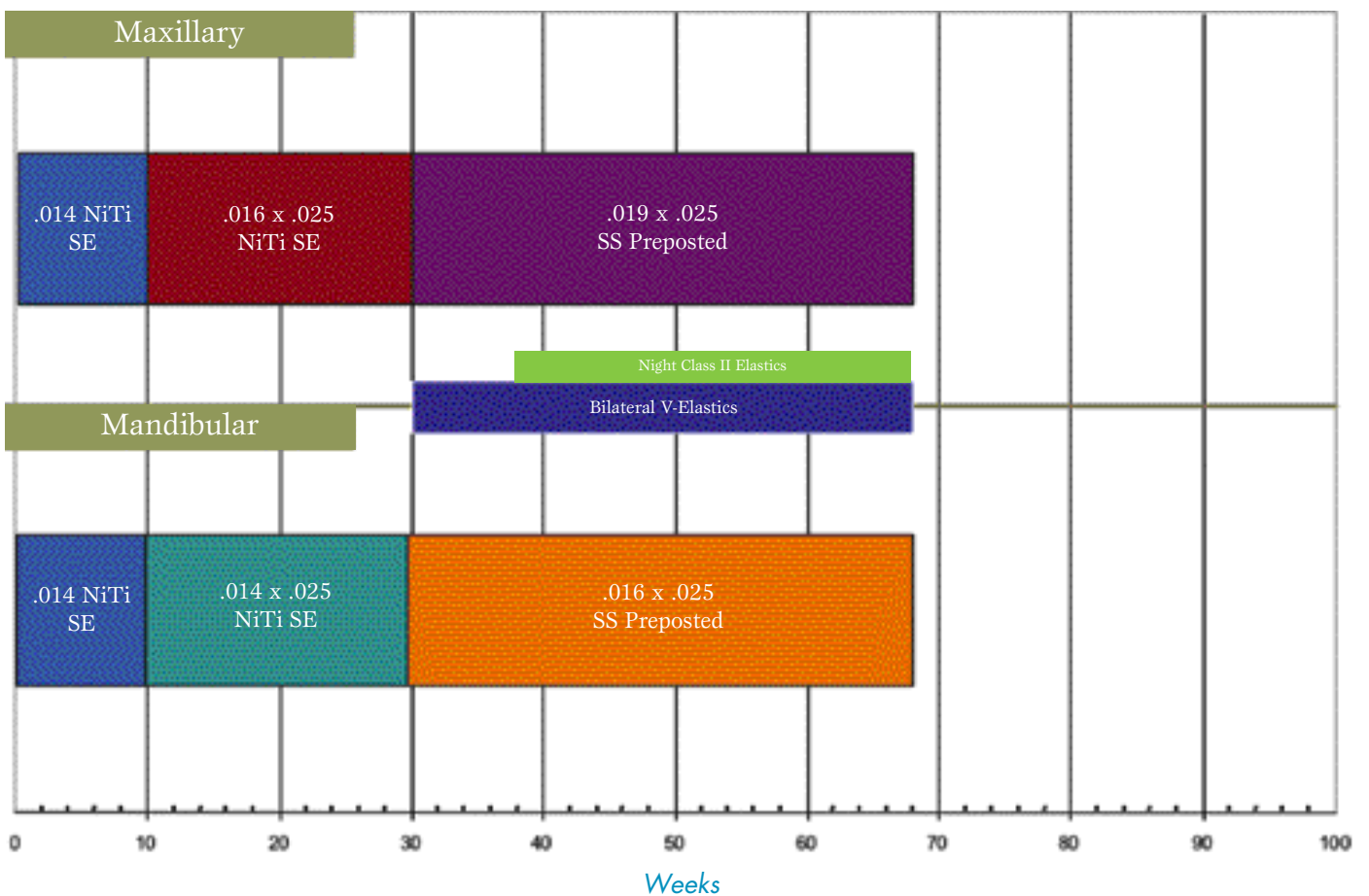


45.0 mm  
.5 mm change

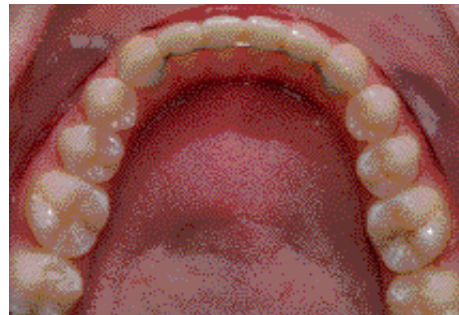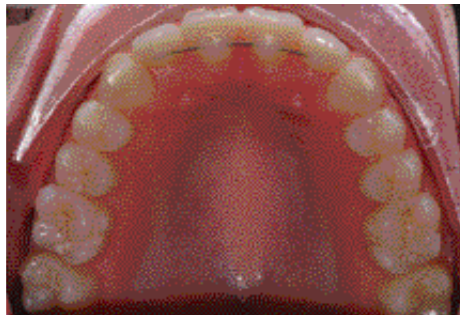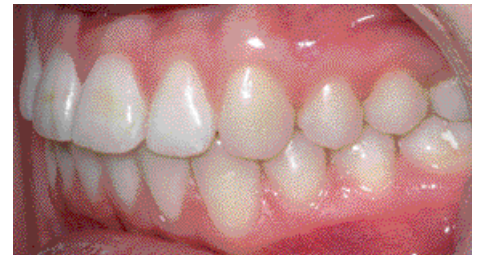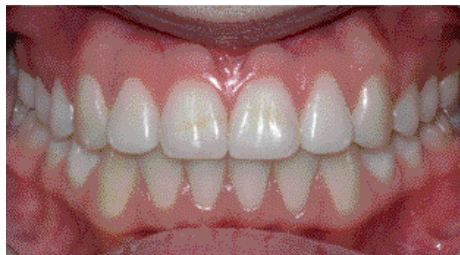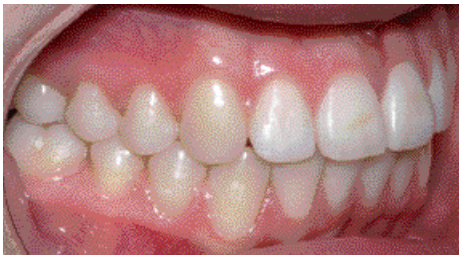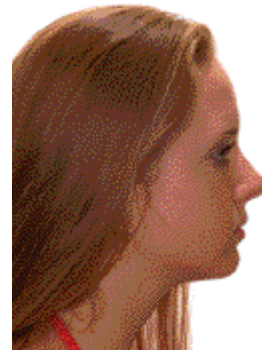**Retention:**

1. Maxillary .016 x .022 Bond-a-Braid archwire bonded lateral to lateral.
2. Mandibular .026 steel round bonded to all teeth cuspid to cuspid due to the severity of crowding.
3. Clear-plastic overlay retainers made for upper and lower arches.
4. Damon splint made for night retention, giving "activator" type of effect until patient is finished growing.

**K.P. Post Herbst Case Summary**



K.P.



One year retention